

Anterior challenge: obtain high esthetics with two different restoration materials and cements.

A case study by Dr. Carlos Eduardo Sabrosa, DDS, MSD, DScD featuring 3M™ RelyX™ Veneer Cement and 3M™ RelyX™ Unicem Aplicap™ Self-Adhesive Resin Cement

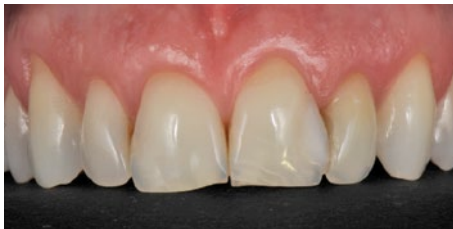
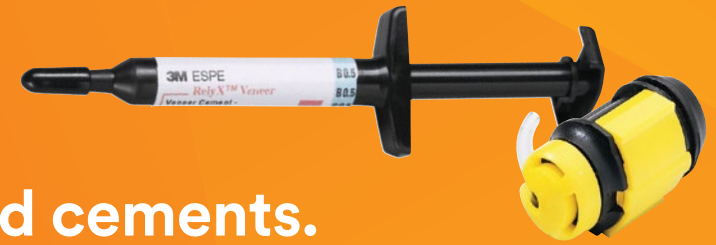
Fig. 1: Younger male patient with failing composite fillings on central well as right lateral incisors. Also in need of a crown on left lateral incisor. Agreement to make three veneers in addition to the crown to improve his esthetics and cover the defects.

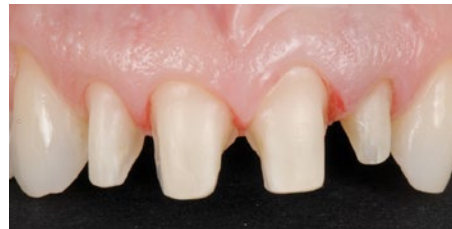

Fig. 2: Situation after tooth preparation.

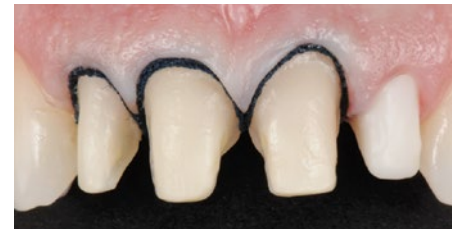

Fig. 3: The placement of two retraction cords per tooth to open up sulcus well for impression taking.

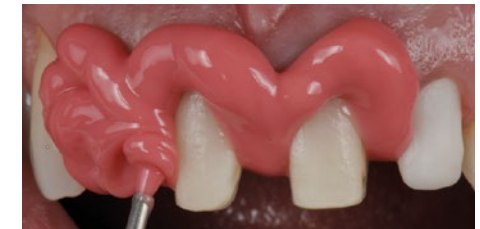


Fig. 4: Application of 3M™ Impregum™ L DuoSoft™ Polyether Light Body Impression material keeping tip well immersed.

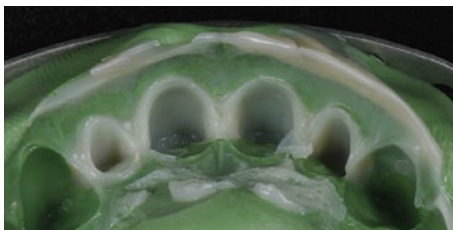


Fig. 5: Making the temporary restoration with 3M™ Protemp™ 4 TempORIZATION Material and a silicone matrix.

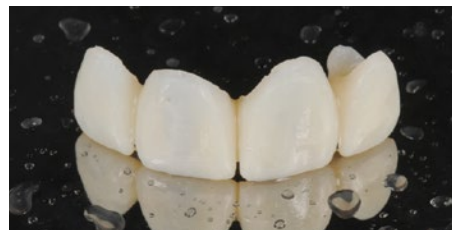


Fig. 6: Finished temporary restoration.

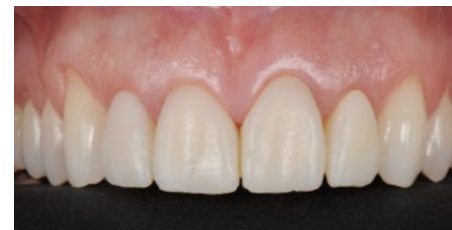

Fig. 7: Temporary in the mouth.

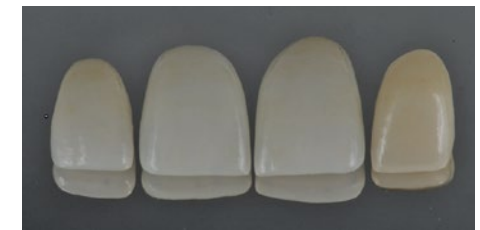

Fig. 8: Fabrication of the final restorations in the laboratory: three Lithium disilicate veneers and a zirconia crown.

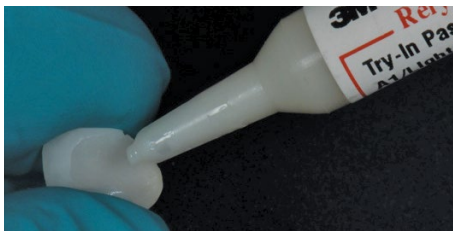

Fig. 9: Try in of the restorations with 3M™ RelyX™ Try-In Paste to determine the optimal cement shade.

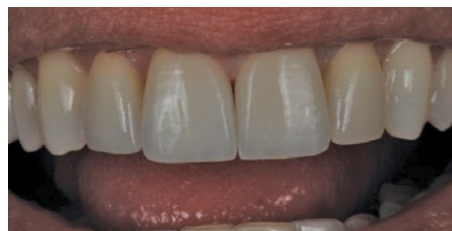

Fig. 10: Aspect after try in.

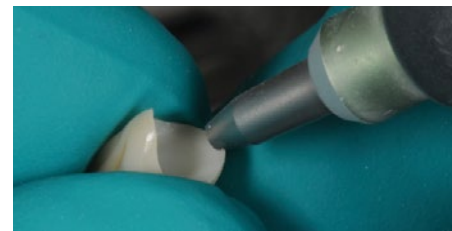


Fig. 11: Pretreatment of the bonding surface of the zirconia crown with aluminum oxide (maximum 2 bar and a grain-size of 30 or 50 µm).

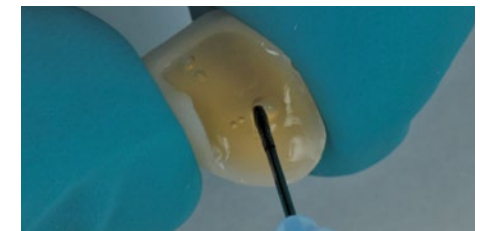


Fig. 12: After etching with hydrofluoric acid the veneers are silylated with 3M™ Single Bond Universal Adhesive, rubbing it in for 20 seconds and then air thinning it gently until no more ripples are observed.

Anterior challenge: obtain high esthetics with two different restoration materials and cements cont.

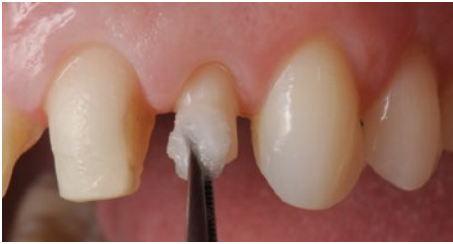

Fig. 13: Prior to cementing the crown the tooth preparation is mechanically cleaned with pumice paste, rinsed and gently dried to leave the surface slightly moist and shiny.



Fig. 14: 3M™ RelyX™ Unicem Aplicap™ Self-Adhesive Resin Cement is directly applied into the previously sandblasted zirconia crown.

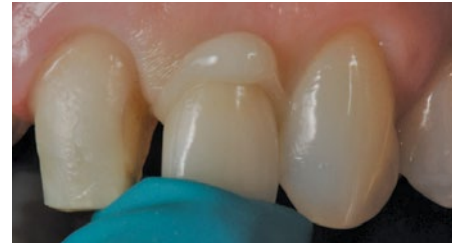

Fig. 15: The crown is firmly seated under finger pressure and the excess removed with a scaler after a 1-2 second tack cure. Final cure for 20 seconds per surface. Finish and polish as needed.

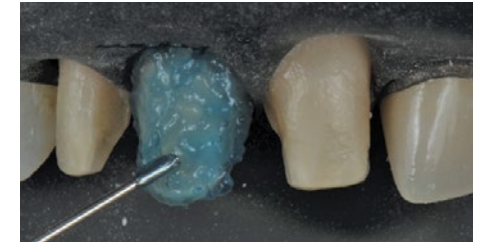

Fig. 16: The veneer preparations are etched with phosphoric acid.

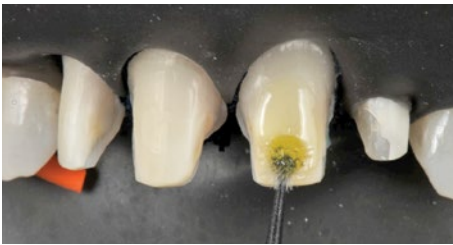

Fig. 17: Apply 3M™ Single Bond Universal Adhesive and rub it in for 20 seconds.

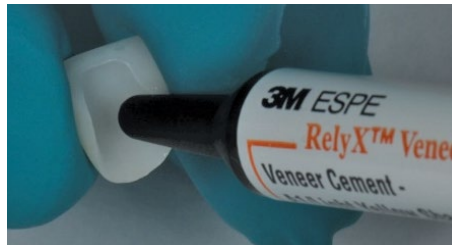

Fig. 18: 3M™ RelyX™ Veneer cement is applied into each of the pretreated veneers.

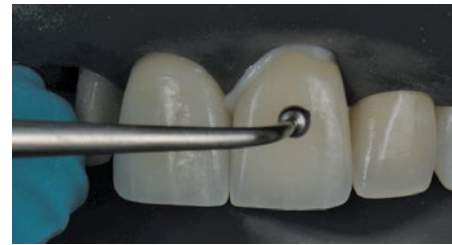

Fig. 19: Each veneer is carefully placed under slight pressure to extrude the excess. A 20 second spot light cure away from the margin is recommended to ensure a stabilized restoration in place prior to cleaning up the excess. Final cure for 30 seconds from all surfaces.

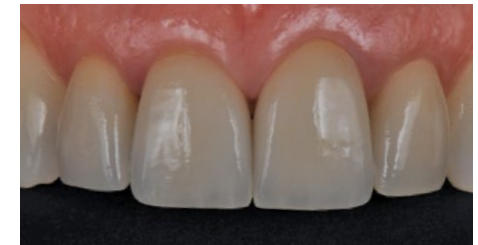

Fig. 20: Final restorations in place.

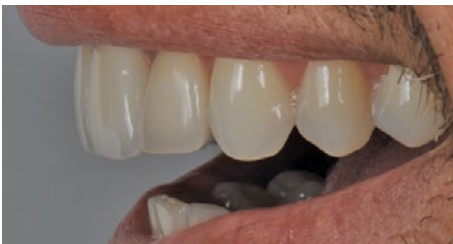

Fig. 21: Lateral view of a happy patient.

3M

3M Oral Care
2510 Conway Avenue
St. Paul, MN 55144-1000 USA

Phone 1-800-634-2249
Web 3M.com/Dental

[3M.com/DentalCements](https://www.3m.com/DentalCements)

Before using the products described, please refer to the instructions for use provided with the product packages.

The featured 3M product may be known with an alternative name in different regions.

3M, Aplicap, DuoSoft, Impregum, Protemp, RelyX and Scotchbond are trademarks of 3M or 3M Deutschland GmbH. Used under license in Canada. All other trademarks are owned by other companies. Please recycle. Printed in U.S.A. © 3M 2017. All rights reserved. Dr. Sabrosa has received an honorarium from 3M Oral Care. 70-2013-7017-1