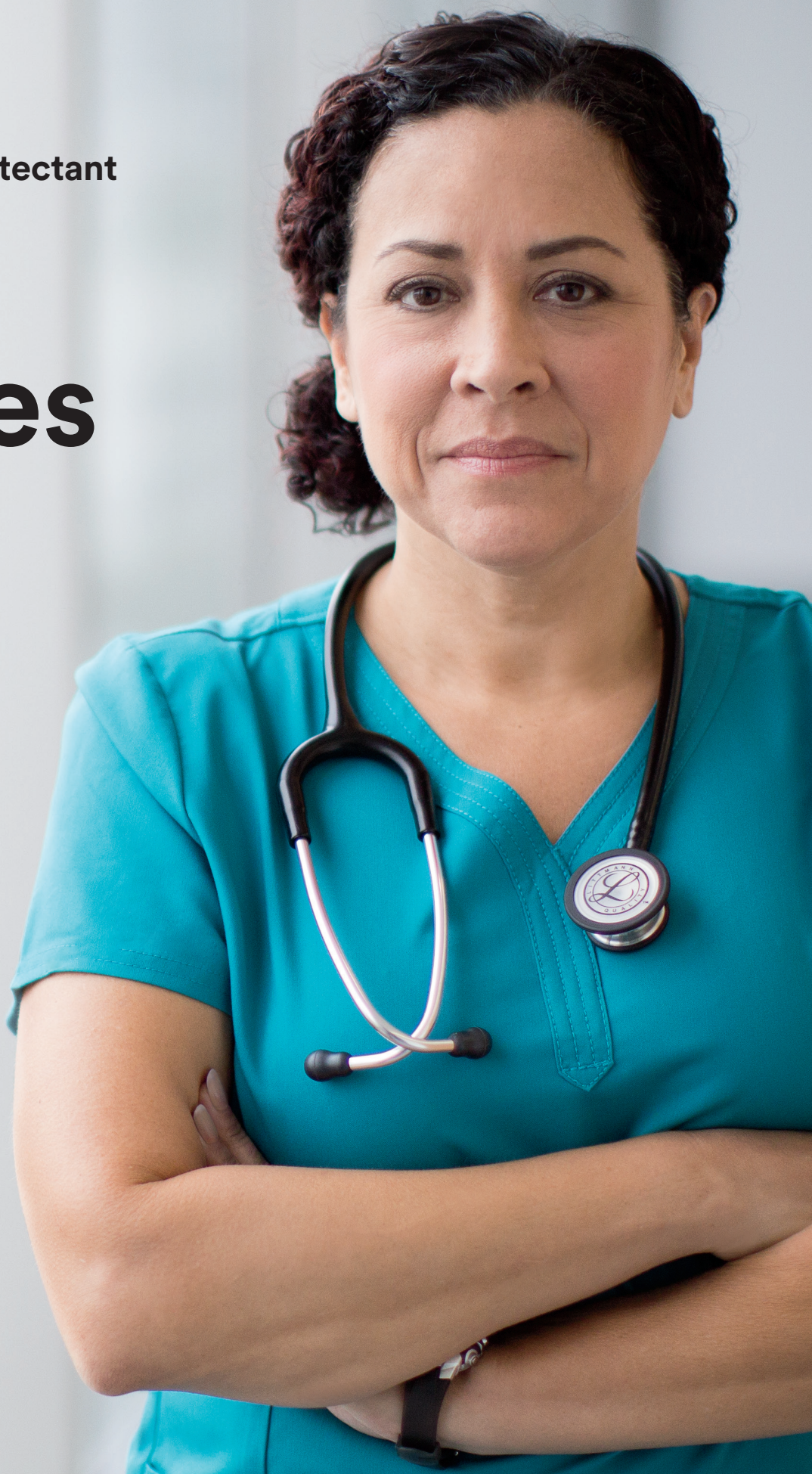

**3M** Science.  
Applied to Life.™

**3M™ Cavilon™**  
Advanced Skin Protectant

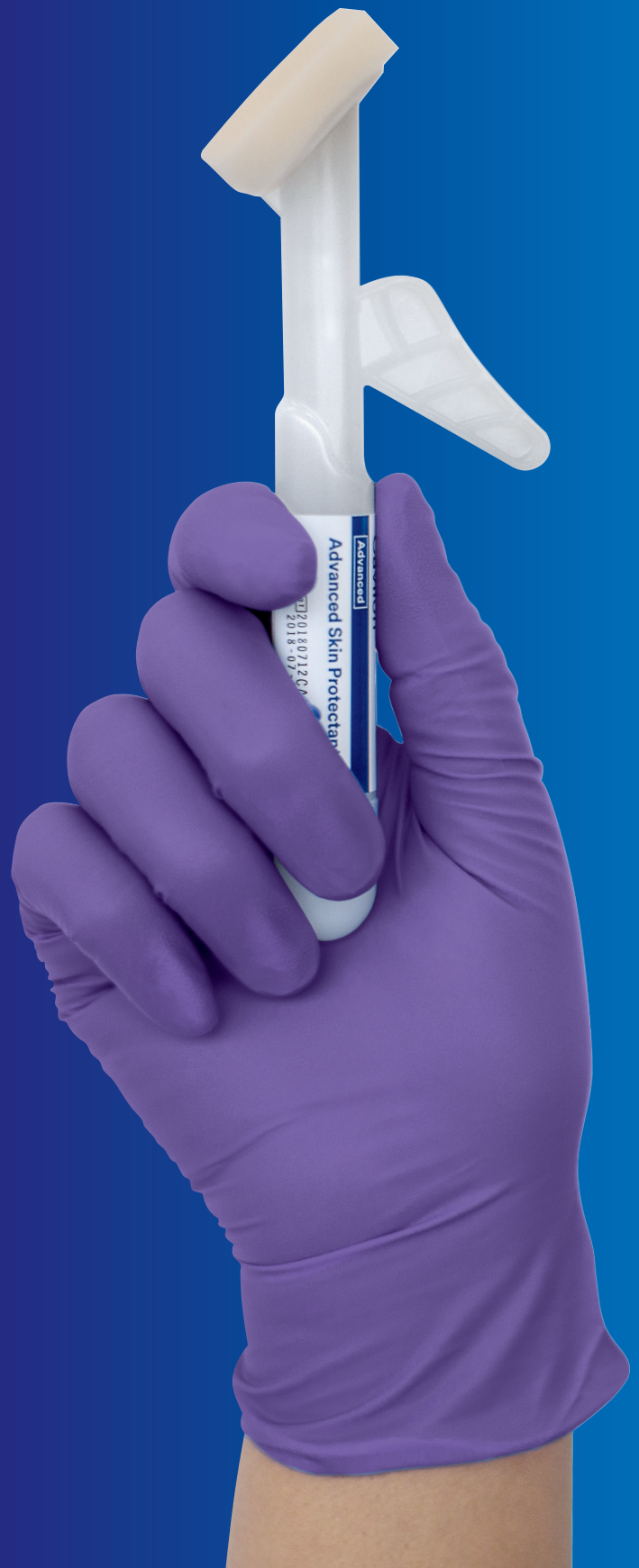# Case Studies





Skin damage presents negative clinical outcomes resulting in potential complications such as infection, pain and suffering, and a poor patient experience. In addition, skin damage increases the time and cost of care.

Exposure over time to factors such as irritants, moisture, friction, shear and adhesives can lead to conditions of skin breakdown. The resulting wet, weepy surface can also bleed and cause pain to your patient. Until now, traditional pastes and ointments have been the only option for protecting this damaged tissue. After using these products, you're well aware of their limitations.



**3M™ Cavilon™ Advanced Skin Protectant combines a unique polymer system with a cyanoacrylate to create a highly durable, ultra-thin, transparent barrier with elastomeric properties.**

## **This barrier has the power to:**

- ▶ Protect against caustic, corrosive body fluids, including liquid stool or gastric fluid<sup>1</sup>
- ▶ Flex and stretch while in place, providing waterproof<sup>1</sup>, irritant-proof skin protection for your patients and residents – even under the most challenging conditions<sup>1</sup>
- ▶ Attach to wet, weepy damaged skin surfaces<sup>1</sup>
- ▶ Create a protective environment that supports healing and helps reduce pain associated with IAD<sup>1</sup>
- ▶ **Additional benefits for you, and your patients and residents:**
- ▶ Avoid the need for frequent reapplication<sup>1</sup>
- ▶ Allows easy, gentle cleansing with **no removal required**
- ▶ Easy-to-use, single-use applicator makes application fast and reduces the potential for cross-contamination possible with traditional products

## **Use Cavilon Advanced Skin Protectant to:**

Prevent and manage moderate to severe skin damage on patients and residents:

- ▶ Moisture lesions/IAD
- ▶ Tube and drain sites
- ▶ Ostomies and fistulas
- ▶ Peri-stomal damage
- ▶ Peri-wound damage
- ▶ Intertriginous dermatitis (skin folds)
- ▶ Skin tears

## **Contents**

- 1 A Case Study using a novel elastomeric barrier for the treatment of severe Incontinence Associated Dermatitis (IAD) in an acute and community setting**  
Fiona Russell, Nurse Consultant Tissue Viability, NHS Grampian
- 2 A case study using a novel elastomeric barrier for the treatment of severe incontinence associated dermatitis for an acutely unwell patient with antibiotic related diarrhoea in an intensive care setting**  
Sarah Pointer, Tissue Viability Nurse, Maidstone and Tunbridge Well NHS Trust
- 3 Use of a high endurance elastomeric skin protectant to treat severe IAD and MASD**  
Valerie Hanssens Msc. Wound Care Specialist – UZ Brussel, Belgium
- 4 Comparing IAD and financial outcome with a novel skin protectant**  
Matthias Van Houdenhove, Pressure Ulcer Prevention Coach, Rehabilitation Unit – A.Z. Sint-Maria Halle, Belgium
- 5 Findings of a multiple-patient evaluation of an advanced elastomeric barrier to treat incontinence associated dermatitis in a large acute trust**  
Sian Fumarola, Senior Clinical Nurse Specialist Tissue Viability and Continence, and Lauren Olenczuk, Tissue Viability Nurse, University Hospitals of North Midlands NHS Trust
- 6 Case series using an advanced silicone-based polymer skin protectant for the clinical management of patients with moisture-associated skin damage (MASD)**  
Karen Laforet MCISc, RN,  
Jade Dias MCISc RN,  
Sukaina Muhammad MCISc RN,  
Mississauga, Ontario

# A case study using a novel elastomeric barrier for the treatment of severe Incontinence Associated Dermatitis (IAD) in an acute and community setting

# 1

Fiona Russell, Nurse Consultant Tissue Viability. NHS Grampian

## Introduction

A 55 year old lady was admitted to hospital with pain and tissue breakdown to perianal region, caused by a combination of 29 fractions of radiotherapy. Rectal CA was diagnosed in November 2017 and she had undergone chemotherapy and radiotherapy. She was referred to the Tissue Viability Service with severe skin loss/moisture lesions to perianal region and apron folds.

## Intervention

On 12/12/17 Tissue Viability visited this lady and reviewed her perianal skin which was very painful and was causing her distress. The decision to use 3M™ Cavilon™ Advanced Skin Protectant was based on the physical and emotional wellbeing of this lady. Ward staff were educated that while Cavilon Advanced Skin Protectant was in situ no other creams or treatments were to be used. The Tissue Viability Team would be coming back to re-apply.

They were advised to cleanse when the patient was soiled with dry wipes wet in warm water, (not to use pre-moistened wipes) or gauze swabs which have been wet in water only. The patient was able to shower if she wanted to but advised no shower gels or soaps and only shower head water to perianal/groins. After the 3rd application of Cavilon Advanced (18/12/17), the patient was discharged home and referred into the care of the District Nurses. The last application of Cavilon Advanced was carried out by the DN on 21/12/17 and the patient's skin was managed by their usual barrier product for ongoing skin maintenance.

**“The instant relief in using Cavilon Advanced Skin Protectant was very evident. This has resulted in a reduction in costs compared to our usual moisture lesion management choice.”**

## Results

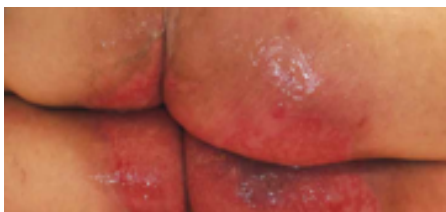The visible improvement can be seen in the images. Pain relief was immediate following the first application of Cavilon Advanced Skin Protectant and within the six days in hospital there was significant physical improvement within the wound.

Taking the variables out of the management of care (due to no other barrier or treatments being required), reduced any confusion with the nursing staff for ongoing management – all they needed to do was cleansing as required. The most outstanding result was the impact Cavilon Advanced Skin Protectant had on the patient's quality of life, she felt that this product really helped her physical and emotional wellbeing.

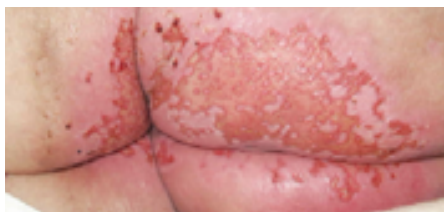## Conclusions

Only four applications of Cavilon Advanced were required to resolve this condition. Prior to Cavilon Advanced, we would have used our wound formulary barrier film which would have been applied every 48-72 hours depending on the volume and frequency of the stool, the soiled area would have been cleansed with a pH neutralising foam cleanser. This process would have been assisted by the nursing staff due to the pain and distress this person felt having this procedure done. Pain and distress experienced during this procedure is something that should not be 'normalised' as expected.

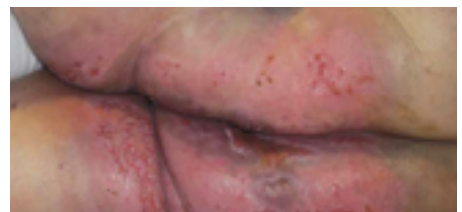For the patient, IAD is a painful condition which can increase the risk of complications such as secondary infection and pressure ulcers. The instant relief in using Cavilon Advanced Skin Protectant was very evident and ability to reduce the pain of IAD and subsequent cleansing improved the overall comfort and wellbeing for the patient. This has resulted in a reduction in costs compared to our usual moisture lesion management choice. This was not just monetary but nursing time and patient involvement in their own care.



**12 December 2017**  
Presentation to Tissue Viability Service and first application of Cavilon Advanced (in hospital)



**15 December 2017**  
Second application of Cavilon Advanced (in hospital)



**18 December 2017**  
Third application of Cavilon Advanced (discharged home)

# A case study using a novel elastomeric barrier for the treatment of severe incontinence associated dermatitis for an acutely unwell patient with antibiotic related diarrhoea in an intensive care setting

Sarah Pointer, Tissue Viability Nurse, Maidstone and Tunbridge Well NHS Trust

# 2

## Introduction

A 62 year old lady was admitted for a right ureteric stent insertion for hydronephrosis. Post procedure she became hypoxic, optiflow was commenced and she was transferred to the Intensive Care Unit. On day 3 she was intubated for increasing oxygen requirement. Urine microscopy, culture and sensitivity grew e-coli and antibiotics (Tazocin and Gentamicin) were administered. After a failed extubation the patient went on to require inotropic support treatment for fast atrial fibrillation. She was successfully extubated on day 6 and was treated successfully for urosepsis and type 1 respiratory failure.

Unfortunately she developed antibiotic related diarrhoea requiring a faecal management system which was inserted after 24 hours of diarrhoea. Extensive excoriation to buttocks had already occurred at that point.

## Intervention

3M™ Cavilon™ Advanced Skin Protectant (a polymeric-cyanoacrylate solution intended to cover and protect intact or damaged skin, and is effective on skin that is frequently or continuously exposed to moisture and irritants such as faeces) was commenced.

The patient was reviewed again by Tissue Viability on day 4 after the application of Cavilon Advanced and it was noticed that the excoriation had significantly improved. Medical photography was taken with the patient's consent.

The patient was discharged home into community care and skin care instructions were given to use a pH neutral cleanser and 3M™ Cavilon™ Durable Barrier Cream for ongoing protection and restoration of the skin.

## Results

Only one application of Cavilon Advanced Skin Protectant was required to treat the patients IAD and this enabled a faster recovery and discharge. Without the Cavilon Advanced Skin Protectant, we would have relied on the faecal management system, frequent personal hygiene to keep the area clean and the use of 3M™ Cavilon™ No Sting Barrier Film, which would have required repeated applications.

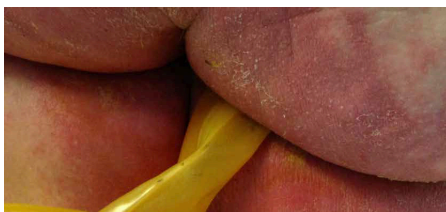
Cavilon Advanced skin protectant allowed for the area of IAD to be completely covered in one application, protecting the skin from the liquid stool and cleansing products. The patient reported that her skin no longer felt sore and tender and this had made her more comfortable in her bed, allowing her to rest and recuperate from her illness.

## Conclusions

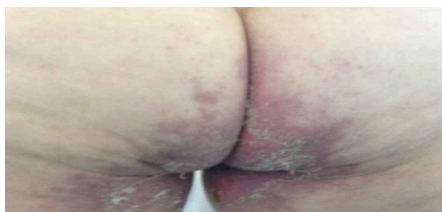The elastomeric properties of Cavilon Advanced Skin Protectant, together with its transparency and durability meant that it was able to provide longer lasting barrier protection and treat severe incontinence associated dermatitis in this critically ill patient, even under the influence of constant liquid stool.

Following this and other successful patient evaluations, Cavilon Advanced Skin Protectant is being incorporated into the Trust Protocol for moderate to severe IAD and is also being explored for its use in prevention of IAD in the intensive care setting.

**“Only one application of Cavilon Advanced Skin Protectant was required to treat the patients IAD and this enabled a faster recovery and discharge.”**



**Day 1**  
First Application of 3M™ Cavilon™ Advanced Skin Protectant



**Day 4**  
Review following the application of 3M™ Cavilon™ Advanced Skin Protectant



# Use of a high endurance elastometric skin protectant to treat severe IAD and MASD

Valerie Hanssens Msc. Wound Care Specialist – UZ Brussel, Belgium

# 3

## Introduction

We evaluated a novel high endurance skin protectant to treat challenging cases of IAD and MASD lesions and also to prevent exacerbation of these lesions. The specific cases were a recto-vaginal fistula resulting in a GLOBIAD Cat 2A IAD, a leaking gastrostomy and an high output enterocutaneous fistula, both leading to excoriated skin lesions.

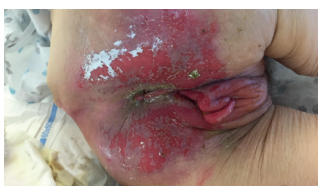## Case 1: Rectovaginal fistula, GLOBIAD Cat.2A

The first application (Picture 1) of a novel high endurance skin protectant was tender and painful, possibly contributed to by the sensitive and irritated tissue. However, 12 hours after the first application the patient reported she was completely pain free.

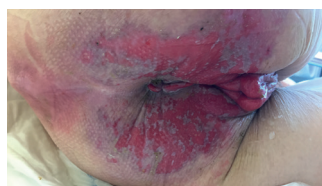Picture 2 shows the lesions two days after the first application. We noted that the diaper adhered to the skin. This is due to residual tackiness. We resolved this by adding a silicone interface 20x30cm between the diaper and skin and continued that just before 14th August. This interface would then be cleansed at every diaper change. Patient reported that she finally had a night of good sleep without pain.

Picture 3 is the result after two applications and taken prior to the third application. The picture shows clear signs of epithelization. Although the patient experienced the application as unpleasant she states that during the cleansing episodes there is no pain anymore.

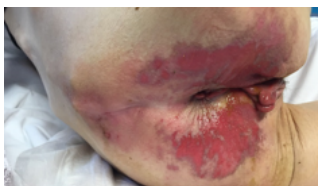Picture 4, we conclude that full epithelization has been achieved and the severe Cat 2A IAD has been healed. Considering the benefit provided to her, the patient decided to use the skin protectant every three days as a preventive measure.



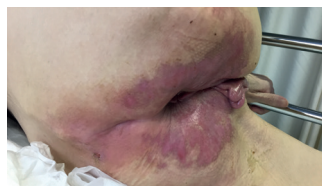
Picture 1: 7 August 2017



Picture 2: 10 August 2017



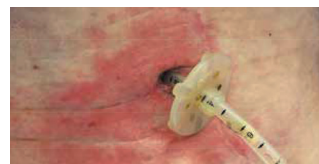Picture 3: 14 August 2017



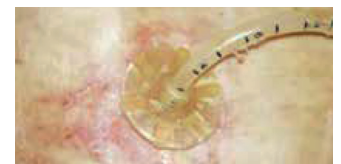Picture 4: 17 August 2017

## Case 2: Leaking gastrostomy

This palliative patient had a leaking gastrostomy for several days. Despite several dressing changes a day, the irritation of the skin became bigger and more painful. The first application (picture 1) of a novel high endurance skin protectant was unpleasant for the patient. However, after 24 hours the patient was pain free. Picture 2 shows that we achieved full epithelization after only one application despite continuous irritant exposure.



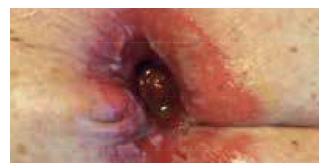Picture 1: 9 February 2018



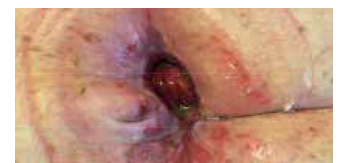Picture 2: 12 February 2018

## Case 3: High output enterocutaneous fistula

In this case the fistula was a communication between the small bowel and the skin, with a daily output of 750ml. Several days of leaking ostomy appliances resulted in a painful partial thickness lesion. The first application (picture 1) of a novel high endurance skin protectant meant that we could use ostomy paste with alcohol to fill the cavity and the skin folds to prevent leakage without creating pain due to the alcohol on the excoriated skin. We applied the skin protectant every 2 days while changing the ostomy appliances.



Picture 1: 18 December 2017



Picture 2: 22 December 2017

## Conclusion

In these challenging clinical situations, a novel high endurance skin protectant created an environment for healing of painful, partial thickness lesions (IAD Cat 2A). Pain reduction and relief was achieved and the patient's quality of life was significantly improved. Based on these outcomes we decided to utilise the high endurance skin protectant in the prevention and treatment of severe IAD lesions and challenging MASD lesions.

**“Pain reduction and relief was achieved and the patient's quality of life was significantly improved.”**

### References

Beeckman D et al. (2017). The Ghent Global IAD Categorisation Tool (GLOBIAD). Skin Integrity Research Group – Universiteit Gent. Available to download from [www.UCVVgent.be](http://www.UCVVgent.be)

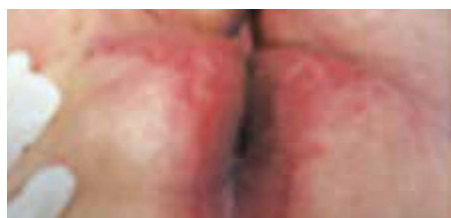# Comparing IAD and financial outcome with a novel skin protectant

Matthias Van Houdenhove

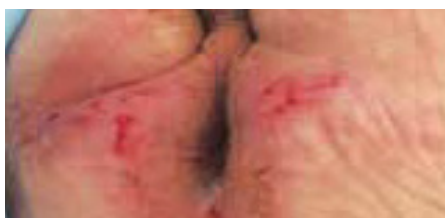Pressure Ulcer Prevention Coach, Rehabilitation Unit –

A.Z. Sint-Maria Halle, Belgium

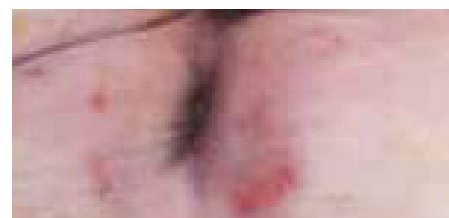
# 4



Before first application



Before second application



No more application needed

## Introduction

As the referent nurse for 'skin integrity' at AZ Sint-Maria Hospital, I was asked to compare the effect on IAD – and financial outcome by using a novel skin protectant, 3M™ Cavilon™ Advanced Skin Protectant (Cavilon ASP) – instead of the common wound treatment as applied on this case. One patient with a typical Cat 2A IAD was chosen to compare treatment and financial outcome by using Cavilon ASP by comparing cost, pain (Wong-Baker faces scale) and time to heal.

**“Application of Cavilon ASP reduces pain from the first application and induces quick recovery of the skin integrity.”**

## Intervention

An 87 year old male with severe UTI (campilobacter, treated with ciprofloxacin 400mg 3/day/7days, starting 26/07/2017), dehydration, dementia and diarrhoea (after two days of AB).

- ▶ 28/07/2017 initial diagnosis of the lesion by the responsible nurse: PU grade 2
- ▶ 01/08/2017 diagnosis by the hospital referent skin integrity: IAD Globiad 2A
- ▶ Treatment from 28/07/2017 – 01/08/2017: 3x/day (because of loosening of the wound dressing due to abundant diarrhoea) application of:
  - ▶ Isobetadine uniwash
  - ▶ Isobetadine dermicum
  - ▶ Isobetadine tulle
  - ▶ Zetuvit compress
  - ▶ Hypafix fixation tape
  - ▶ VAS pain during application 10/10
  - ▶ VAS pain after application 6/10
  - ▶ No healing of the lesion at all on 01/08/2017
  - ▶ Cost/day: € 4,66 (according to amount of products/day)
  - ▶ Cost/(estimated healing time of 20 days by a registered wound nurse)healing: € 93,20
- ▶ Treatment from day 3 ( when diagnosis of IAD GLOBIAD 2A): 3x/week application of Cavilon ASP

## Results

### 1 August 2017

- ▶ First application – after gentle cleansing with 3M™ Cavilon™ Bathing Wipes – one Cavilon ASP applicator.
- ▶ VAS pain during application 2/10
- ▶ VAS pain after application 0/10
- ▶ No further compresses or wound dressing needed
- ▶ Incontinence management: cleansing after every incontinence period with Cavilon bathing wipes and use of usual diaper
- ▶ Cost/application: € 12,00

### 3 August 2017

- ▶ Second application – after gentle cleansing with Cavilon bathing wipes – one Cavilon ASP applicator
- ▶ VAS pain during application 1/10
- ▶ VAS pain after application 0/10
- ▶ No further compresses or wound dressing needed
- ▶ Incontinence management: cleansing after every incontinence period with Cavilon bathing wipes and use of usual diaper
- ▶ Cost/application: € 12,00

### 6 August 2017

- ▶ No more application of Cavilon ASP needed
- ▶ Incontinence management: apply hospital incontinence care protocol. Cavilon Continence Care Wipes after every incontinence episode and additional application of Cavilon Durable Barrier Cream every 48hrs and use of usual diaper
- ▶ No further compresses or wound dressing are needed
- ▶ VAS pain 0/10
- ▶ Cost/healing time: €24,00

## Conclusion

Cavilon ASP is easy to apply and attaches firmly to wet and denuded skin. The product remains flexible and unbroken on the skin for at least two days, even after ongoing episodes of diarrhoea. This feature differentiates Cavilon ASP from the ordinary treatment with isobetadine because it allows the skin to heal underneath the product. Application of Cavilon ASP reduces pain from the first application and seems to be atraumatic from there on. The first application induces quick recovery of the skin integrity. No extra products or wound dressings are needed whilst using Cavilon ASP until healing of the wound. The total cost to healing was approximately 1/4 of the common wound treatment cost, with 1/3 less of the common healing time. Ongoing use of this product on IAD shows similar benefits.

# Findings of a multiple-patient evaluation of an advanced elastomeric barrier to treat incontinence associated dermatitis in a large acute trust

# 5

Sian Fumarola, Senior Clinical Nurse Specialist Tissue Viability and Continence, and Lauren Olenczuk, Tissue Viability Nurse, University Hospitals of North Midlands NHS Trust

## Introduction

A multiple-patient evaluation of Cavilon advanced skin protectant was carried out in a large, acute teaching hospital. The selection criteria for evaluation participants was patients with moderate to severe moisture lesions caused by exposure to urine and/or faeces (IAD). They were selected from across ITU/HDU, Renal, Surgical G.I. and Paediatric wards.

## Intervention

The Skin Protectant was applied twice weekly, while all other barrier products were excluded. Regular and appropriate cleansing was continued, using plain water with dry wipes. Bathing wipes were also allocated to the patient group; however these did not contain any Dimethacone-based barriers (3-in-1 Wipes).

The Tissue Viability Team applied the barrier and monitored patient progress. Areas of skin damage/breakage were reassessed and measured prior to each application. Clinical photography was also used, with patient consent prior to, and during the evaluation period. Pain scores (0-5 scale) were also taken, prior to and during application, and during regular bathing and cleansing. During the evaluation, each member of the Tissue Viability team completed a survey, to gather feedback of their experiences using the product (current practices, ease/frequency of application) and those of the patient (levels of comfort/pain reported).

**Staff had stated that patients were in less pain and were much more compliant with cleansing and repositioning due to seeing quick results and less discomfort on movement.**

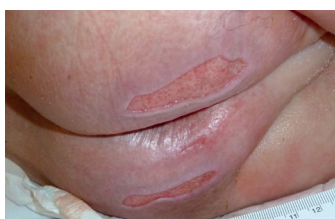## Results

Patients required less frequent application of the Cavilon advanced skin protectant, compared to regular barrier products used. This resulted in a reduction of pain experienced by the patients when compared to the removal of thicker pastes and topical treatments. The benefit of this was not only a more comfortable experience for the patient, but also less anxiety around pain associated with cleansing and a reduction in friction and shear due to less frequent application and removal of barrier products.

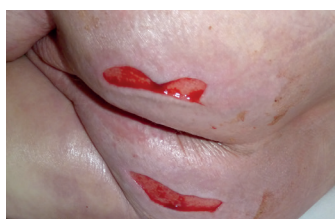The elastomeric properties of Cavilon Advanced Skin Protectant, along with its' transparency and durability meant that it was able to provide longer lasting barrier protection and support wound healing in patients with moderate to severe IAD, while still allowing regular cleansing to take place. .

## Conclusion

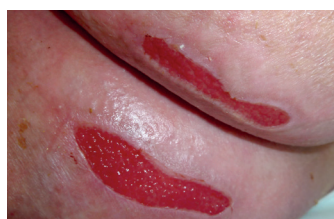Current practices within the Trust mean barrier products are more frequently applied and removed when used on patients with severe IAD. Due to the need for frequent cleansing, barrier products must be re-applied after every 1–3 episodes of incontinence, depending on the product used. Frequent cleansing, combined with the raised pH of skin means that patients often report increased pain and distress, especially during episodes of incontinence. An ideal barrier product for severe IAD would require less frequent application, provide irritant-proof protection and create an environment that allows skin to heal while regularly cleansing can continue.



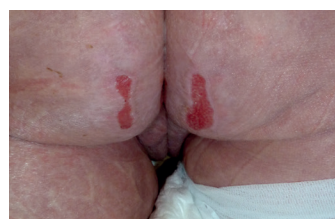Application day 1



Application day 2



Application day 3



Application day 4

52 year old female. PMH: anxiety, depression, smoker, excessive alcohol use, alcohol liver disease, alcohol induced brain disease and epilepsy. Bed bound on admission, doubly incontinent with Bristol Stool Type 6–7, requiring 2–3 hourly incontinence care.



# Case series using an advanced silicone-based polymer skin protectant for the clinical management of patients with moisture-associated skin damage (MASD)

# 6

Karen Laforet MCISc, RN, Jade Dias MCISc RN,  
Sukaina Muhammad MCISc RN, Mississauga, Ontario

## Introduction

Moisture associated skin damage (MASD) results in inflammation and erosion of the skin caused by prolonged exposure to wound exudate, fistula drainage, urine, stool or perspiration.<sup>1</sup> The primary principle of treatment is to remove the moisture and protect the skin from further injury. The challenge is finding a product that mimics skin's natural function without causing undo harm through application and removal. The community nursing clinics were asked to assess the effectiveness of an advanced breathable silicone-based polymer skin protectant to assess efficacy in treating and preventing MASD.

## Intervention

Seven patients with different MASD etiologies were chosen in place of other skin barrier products. Four patients suffering with periwound moisture-associated dermatitis. All four patients had long-standing wounds that were highly exudative with chronic dermatological issues as a result. One patient had cellulitis secondary to incontinence-associated dermatitis (IAD). Blistering, edema and excoriation resulted. Two patients with peristomal moisture-associated dermatitis were selected due to the chronicity of the problem. The advanced silicone-based polymer skin protectant (AS-BPSP) was applied following manufacturer's instructions for six weeks (or less) dependent on clinical need. The affected skin area was cleansed using 0.9% NaCl solution or warm tap water, patted dry with woven gauze and the skin protectant applied as per manufacturer's directions. Patients were assessed twice weekly for pain level, maceration, erythema, inflammation, irritation or skin breakdown. Product was re-applied weekly and as needed. Four examples are presented here.

### Case 1

53 yr. old male with diabetes admitted for management of neuropathic foot ulcer. Recurring skin breakdown on heel and posterior foot was caused by excessive wound exudate (Fig 1). AS-BPSP was applied twice weekly at each dressing change for a total of 18 applications over six weeks. By end of week four, maceration and inflammation was resolved (Fig 2).

### Case 2

76 yr. old male with long-standing G-tube in situ developed peristomal skin breakdown (Fig 3). Previous skin barriers were ineffective. The AS-BPSP was applied weekly during the six-week trial period. Erythema and excoriation were noticeably improved (Fig 4).

### Case 3

79 yr. old male with long-standing mixed arterial-venous leg ulcers. Maceration has been an ongoing problem causing periwound damage and breakdown (Fig 5). AS-BPSP was started in the hopes of reducing

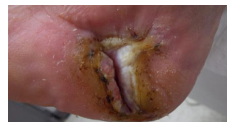

Fig. 1

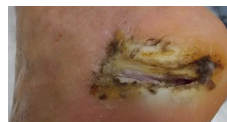

Fig. 2

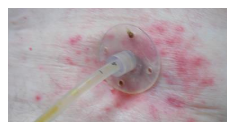

Fig. 3

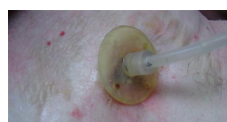

Fig. 4

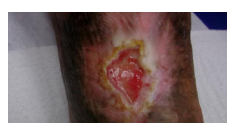

Fig. 5

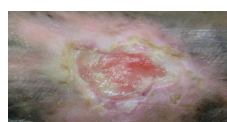


Fig. 6

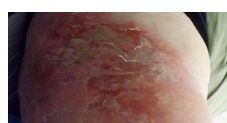


Fig. 7

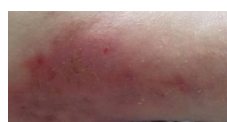

Fig. 8

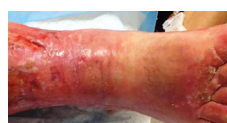

Fig. 9

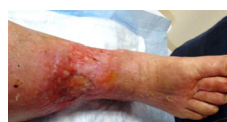

Fig. 10

maceration. Peri-wound skin improvement noted after four weeks of applying the AS-BSP. Maceration reduction resulting in changing dressing changes to twice weekly dressing (Fig 6).

### Case 4

77 yr. old female with leg ulcers secondary to veno-lymphedema developed excoriation and blisters to right side from hip to toes following urinary incontinence. Cellulitis was present in the groin, mid-lateral thigh to knee then from mid-calf to the toes. The right lateral thigh had multiple blisters and the lower leg and foot were excoriated, edematous & highly exudative (Fig 7 & 9). AS-BPSP was applied once in the first week to all affected areas, peri-wound, between toes and into groin. At day 5, erythema, edema, and exudate were significantly reduced. (Fig 8 & 10).

## Results

The skin product attached quickly and easily to wet and denuded skin (Fig 7). Application was atraumatic even on painful wounds (Fig 9). Patients noted a reduction in pain soon after application. The MASD signs and symptoms improved for all case-series patients. Peri-wound maceration and associated erythema and irritation was resolved for patients with wounds and one patient's dressing frequency was reduced once the denuded skin seepage stopped. The patient with IAD and severe excoriation showed the quickest response and benefit (Fig 8 & 10). Patients with drains, while a small sample size (N = 2), did not notice any discoloration caused by wearing clothes or activities, nor flaking of the skin with product in situ.

## Conclusion

MASD is a common problem for many patients with different etiologies. The introduction of an advanced silicone-based polymer skin protectant that is breathable, waterproof and flexible when attached to the skin has shown positive results in this small case series. Ongoing use for selected patients has continued to show similar benefits.

## References

- 1 Gray M, et al. Moisture-associated skin damage: overview and pathophysiology. 2011. JWOCN. May-Jun;38(3): 233-41



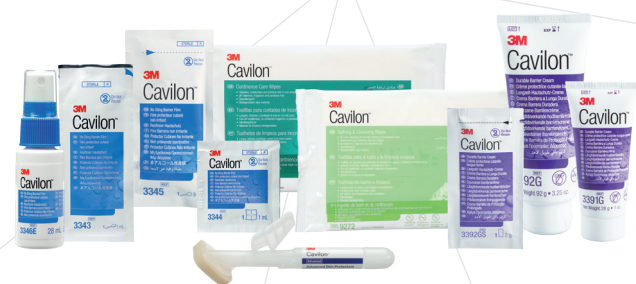
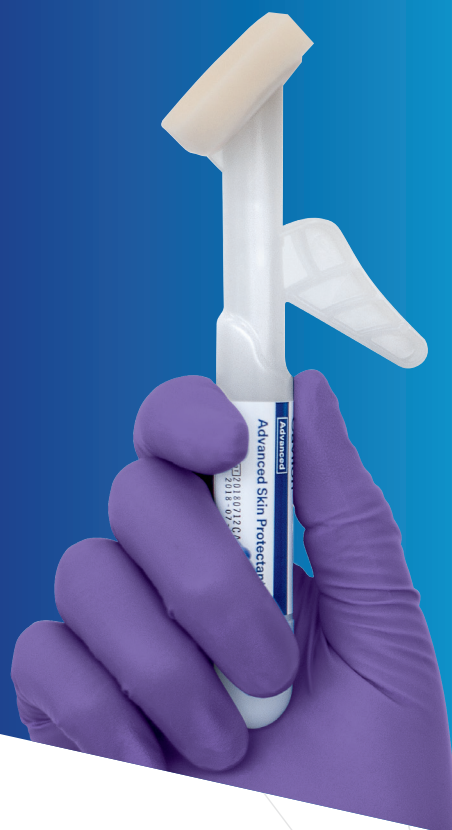


## Ordering information

### 3M™ Cavilon™ Advanced Skin Protectant

NHSSC code	Cat.No.	Description	Items/box
ELY801	5050G	2.7ml Foam applicator (sterile)	20



### To find out more:

 [3M.co.uk/endIAD](https://3M.co.uk/endIAD)

 **0330 053 8938**

 **C3SD@mmm.com**

**3M United Kingdom PLC**  
Charnwood Campus  
10 Bakewell Road  
Loughborough  
Leicestershire  
LE11 5RB  
01509 611611

**3M Ireland**  
The Iveagh Building  
The Park  
Carrickmines  
Dublin 18  
Ireland  
00 353 (01) 280 3555

GF211.  
3M and Cavilon are trademarks of the 3M company.  
© 3M 2018. All rights reserved. J428879.

