

Predictable Implant Impressions Using 3M™ Impregum™ Soft Quick Step Polyether Impression Material

Open Tray/Pick-up Technique

Izchak Barzilay D.D.S., Cert. Prosth., M.S., F.R.C.D.(C)

A 31 year old female patient presented for clinical recall evaluation after not being seen for five years. Her initial treatment involved restoration of a missing upper right lateral incisor with an osseointegrated external hex implant of narrow diameter. The restoration was designed to be retrievable and had functioned well. The patient had noticed over the past six months that the crown no longer seemed in place and appeared to be rotated. On presentation, the implant crown was firm and non-mobile. Radiographic assessment (Figure 1) showed an apparently well integrated implant with bone levels that had changed very little since initial restoration. After removal of the crown and abutment, ISQ values and clinical assessment suggested that the implant was stable and healthy. Examination suggested that there was movement of the other teeth in relation to the implant and the decision was made to fabricate a new restoration for this implant.

A pickup impression coping was secured to the implant and seating was verified (Figure 2). This impression coping is designed to stay in the impression material when the impression is removed from the mouth. The central screw of the impression coping must exit the impression tray while the impression is setting so one can disengage the screw and then remove the impression.

It was decided that a 3M™ Directed Flow Impression Tray (Figure 3) would be used to make the impression. An appropriate sized tray was chosen and tried in for fit.

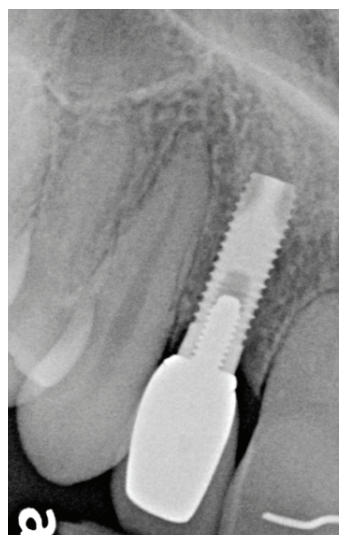


Figure 1. Implant radiograph at recall appointment shows stable bone levels and a secure restoration.

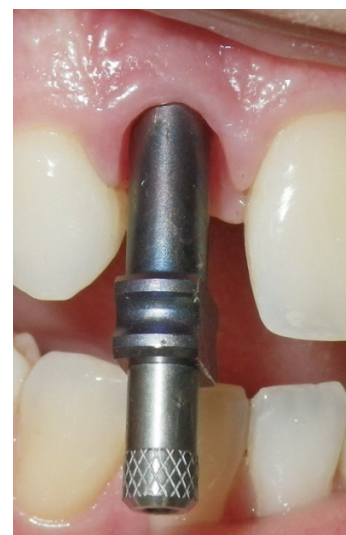
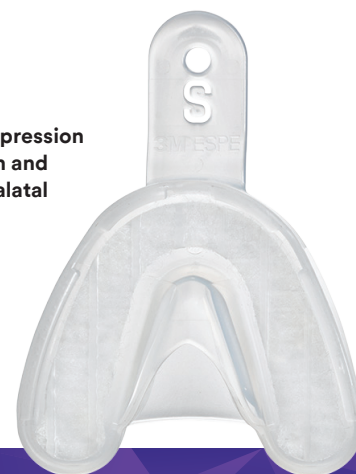
Figure 2. A pickup impression coping has been secured to the implant. Note the central screw which extends out of the implant impression sleeve.

Figure 3. The 3M™ Directed Flow Impression Tray has been chosen for its strength and handling characteristics. Note the palatal reservoir.



This tray was chosen for several reasons:

- It fits well into the patient's arch
- It needs no adhesive
- It is secure and rigid
- It is easily adjustable, and
- The tray has the unique feature of incorporating a palatal reservoir so that when used, the excess impression material that escapes out the distal portion of the tray can be scooped up with a mirror and housed within this area thereby keeping the mouth clear and creating a more gag free impression.

A marking medium was placed on the top surface of the implant impression screw and this marking was transferred to the inside of the tray by seating the tray intraorally (Figure 4). An acrylic bur was used to create a hole in the base of the tray (Figure 5) and the impression tray was then tried in the mouth to ensure that there was clear access to the impression screw (Figure 6).

The impression material chosen for this situation was a polyether based material. This material was chosen for a several reasons:

- Polyether is inherently hydrophilic. With the mouth always being wet, this is a good choice in impression materials for all intraoral applications.
- Polyether is rigid enough to support an implant impression coping without distortion or movement.
- It is easily injected through an impression syringe in either a monophasic or dual phase technique.
- It is easily poured in the lab using many stone formulations.
- It is accurate and can be poured multiple times if needed.
- It has multiple setting times to choose from.

A monophasic technique was chosen since a medium body material shows ideal characteristics in terms of rigidity and detail capture.

A 3M™ Intra-oral Syringe is loaded directly from the 50ml cartridge and set aside (Figure 8). The syringe has not yet been activated. Blue rope wax is placed into the end of the impression screw to make sure that no impression material gets lodged in this area (Figure 9). This facilitates future screw retrieval using an appropriate driver.

The area of interest is dried using compressed air and isolated. The impression syringe is activated and an initial amount of impression material is "bled" from the impression syringe tip (Figure 10). Impression material is then syringed around the impression coping and the neighboring teeth. While this is being done, the impression tray is loaded with the same medium body (monophasic) polyether material that is dispensed from a 3M™ Pentamix™ 3 Automatic Mixing Unit (Figure 11). Once loaded, the tray is seated to place so that the impression coping screw can be visualized protruding through the impression tray (Figure 12). The area is wiped away over the impression screw and the tray is held in place for the setting time prescribed by the manufacturer. Once the impression is set, the impression screw is unscrewed (Figure 13) and the impression is removed from the mouth (Figure 14). The impression coping is picked up in the impression material and can be seen inside the impression. An implant lab analogue (replica) is then connected to the impression coping by positioning it onto the impression coping and securing the impression screw from the opposing end of the tray (Figure 15). The impression is now ready to be poured.

The new prosthesis is now in place and had addressed the malposition issues that were initially evident when the patient presented for treatment (Figure 16).

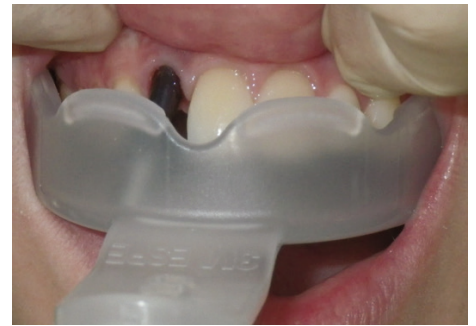

Figure 4. The 3M™ Directed Flow Impression Tray has been chosen for its strength, handling characteristics and palatal reservoir.

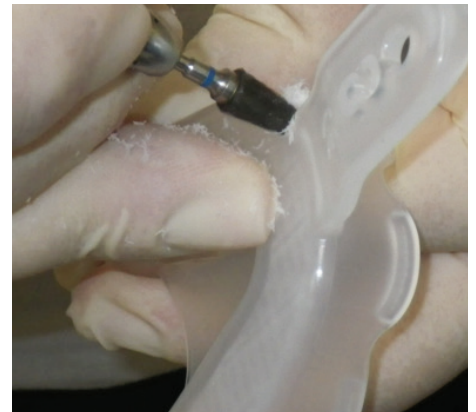

Figure 5. An acrylic bur is being used to cut a hole in the tray to access the impression screw.

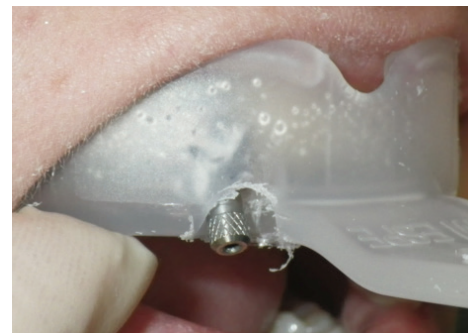

Figure 6. The 3M™ Directed Flow Impression Tray is being tried in the mouth to make sure that the impression screw is accessible.

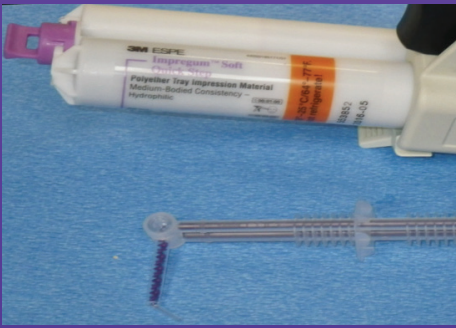

Figure 7. A 3M™ Intra-oral Syringe is ready to be loaded with 3M™ Impregum™ Soft Polyether Impression Material.

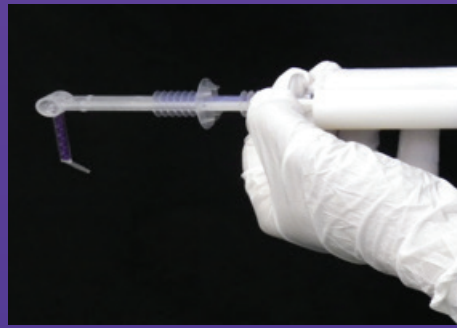

Figure 8. The 3M™ Intra-oral Syringe is loaded from the hand held gun but not yet activated.

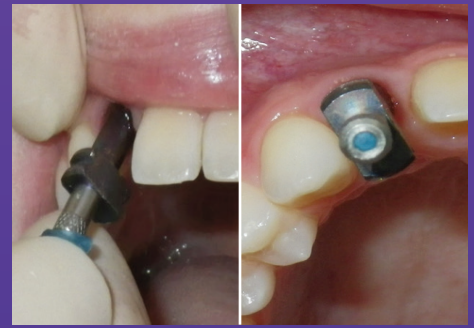


Figure 9. Wax is placed on the impression screw to obturate the driver receptacle.

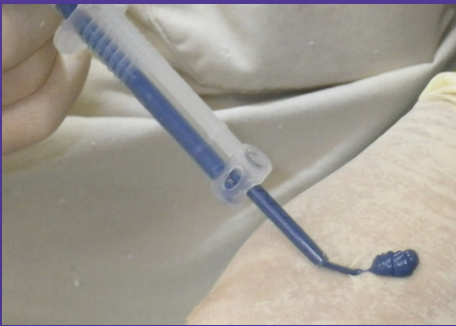

Figure 10. The 3M™ Intra-oral Syringe is activated and must be bled before using for final impression.

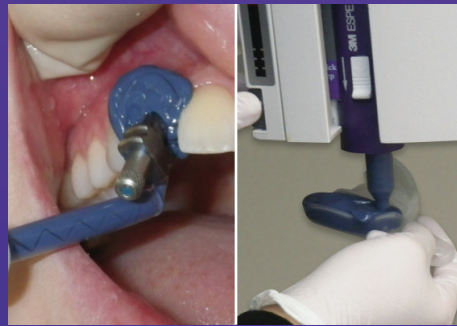

Figure 11. Inject impression material around the impression coping while the dental assistant is loading the 3M™ Directed Flow Impression Tray using the 3M™ Pentamix™ 3 Automatic Mixing Unit.

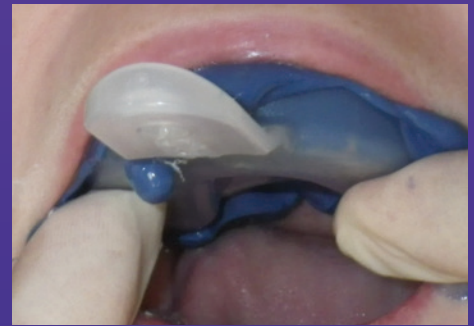

Figure 12. The 3M™ Directed Flow Impression Tray has been loaded and is seated intraorally. Note the extrusion of impression material in the area of the impression coping.

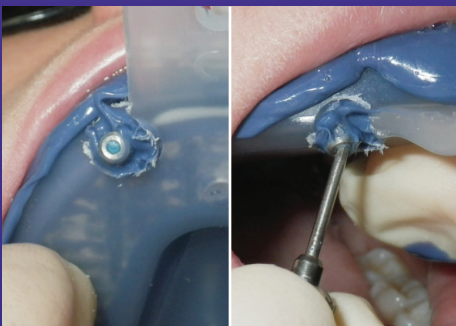


Figure 13. Once the 3M™ Impregum™ Soft Polyether Impression Material has set, use an implant driver to unscrew the impression screw. Remove the 3M™ Directed Flow Impression Tray.



Figure 14. The impression has been removed from the mouth and is ready for inspection.

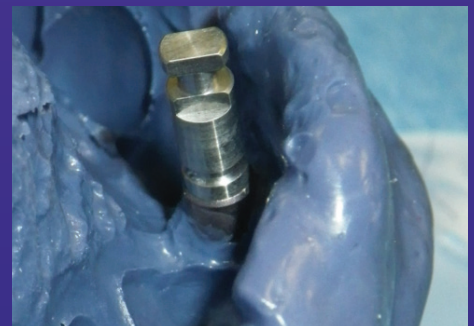
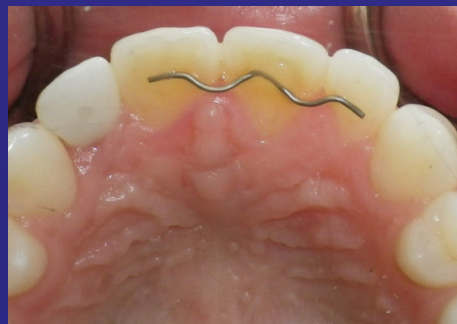
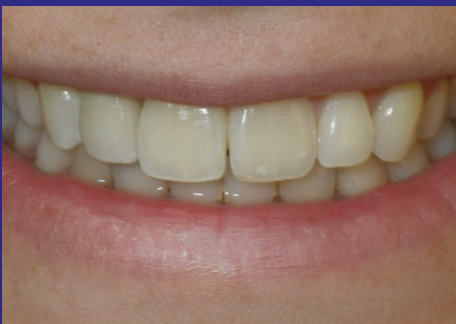Figure 15. Place an implant lab analog into impression coping and secure with the screw. The impression is now ready to be sent to the dental laboratory for pour up and crown fabrication. Note the incredible detail and accuracy seen in the 3M™ Impregum™ Soft Polyether Impression Material.



Figures 16a and 16b. Final insertion of implant crown 12.



Dr. Izchak Barzilay received his DDS from the University of Toronto in 1983, a Certificate in Prosthodontics from the Eastman Dental Center in Rochester, NY in 1986, and a MS from the University of Rochester in 1991. He is currently Head of the Division of Prosthodontics and Restorative Dentistry at Mt. Sinai Hospital in Toronto, Ontario.

Dr. Barzilay past credentials include: Adjunct Assistant Professor, Division of Prosthodontics of the Eastman Department of Dentistry, University of Rochester, Rochester, NY; Professor, George Brown College of Applied Arts and Technology — Denturism Program, Toronto, ON; Associate in Dentistry, University of Toronto, Toronto, Ont.; Incoming Prosthodontic Examiner in Chief – Royal College of Dentists of Canada; Past - President of the Association of Prosthodontists of Canada; Past President - Ontario Study Club for Osseointegration.; Advisory Board - International Society for Digital Dentistry; Medical Advisory Board Member – Sjogren’s Society of Canada,; Publication reviewer for Journal of Esthetic and Restorative Dentistry, and is in private practice limited to prosthodontics and implant dentistry in Toronto, Ont.

He has published on various topics including immediate implants, bonding plastics to various metals and other material and implant related topics. He has been awarded the Tylman Award (American Academy of Crown and Bridge Prosthodontics), Prosthodontics Research Award (International Association for Dental Research), Buonocore Award (American Association for Dental Research Rochester Chapter), the Essay Award (American College of Prosthodontics), the International Journal of Oral and Maxillofacial Implants-Best Paper-1996, the A.B. Hord Master Teacher Award (University of Toronto) and the Division of Prosthodontics 2007 Alumni Award (University of Rochester Eastman Dental Center). Dr. Barzilay holds fellowships in the Academy of Prosthodontics, Academy of Osseointegration, Royal College of Dental Surgeons of Canada, Pierre Fauchard Academy, Academy of Dentistry International and the International College of Dentists.

Dr. Barzilay has received an honorarium from 3M Oral Care.



3M Oral Care
2510 Conway Avenue
St. Paul, MN 55144-1000 USA

Phone 1-800-634-2249
Web 3M.com/Dental

3M.com/dental

3M, Impregum and Pentamix are trademarks of 3M. Used under license in Canada. Please recycle. Printed in U.S.A. © 3M 2017. All rights reserved.