

Case Study: 3M™ Clarity™ Aligners

Space Closure and Missing Bicuspid in a Teen

Age: 17

Chief concern: Canine sticks out

Case diagnostics: Moderate crowding, Class I, missing teeth and midline off

Total number of aligners: Completed 56 aligners of 63 aligners

Wear interval: Weekly

Treatment time: 16 months

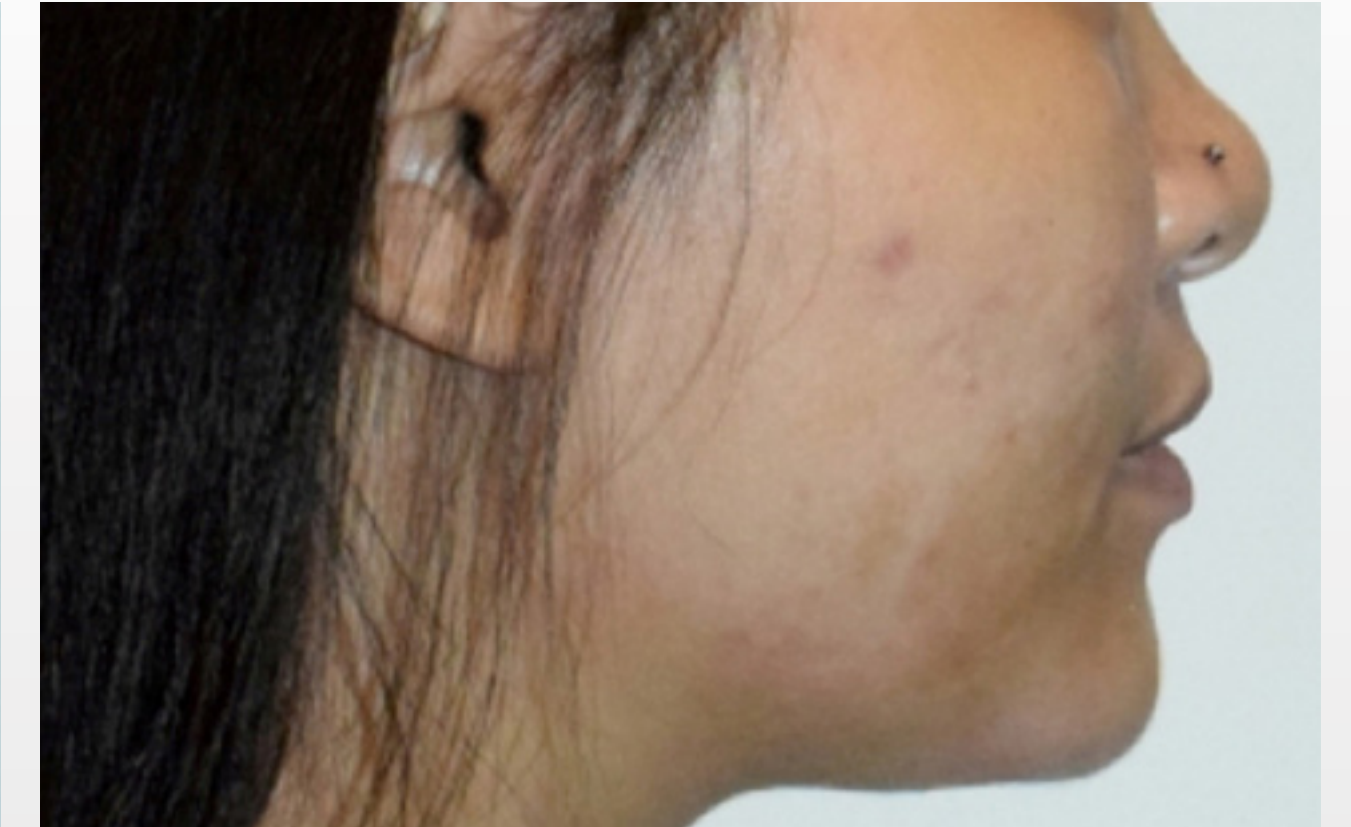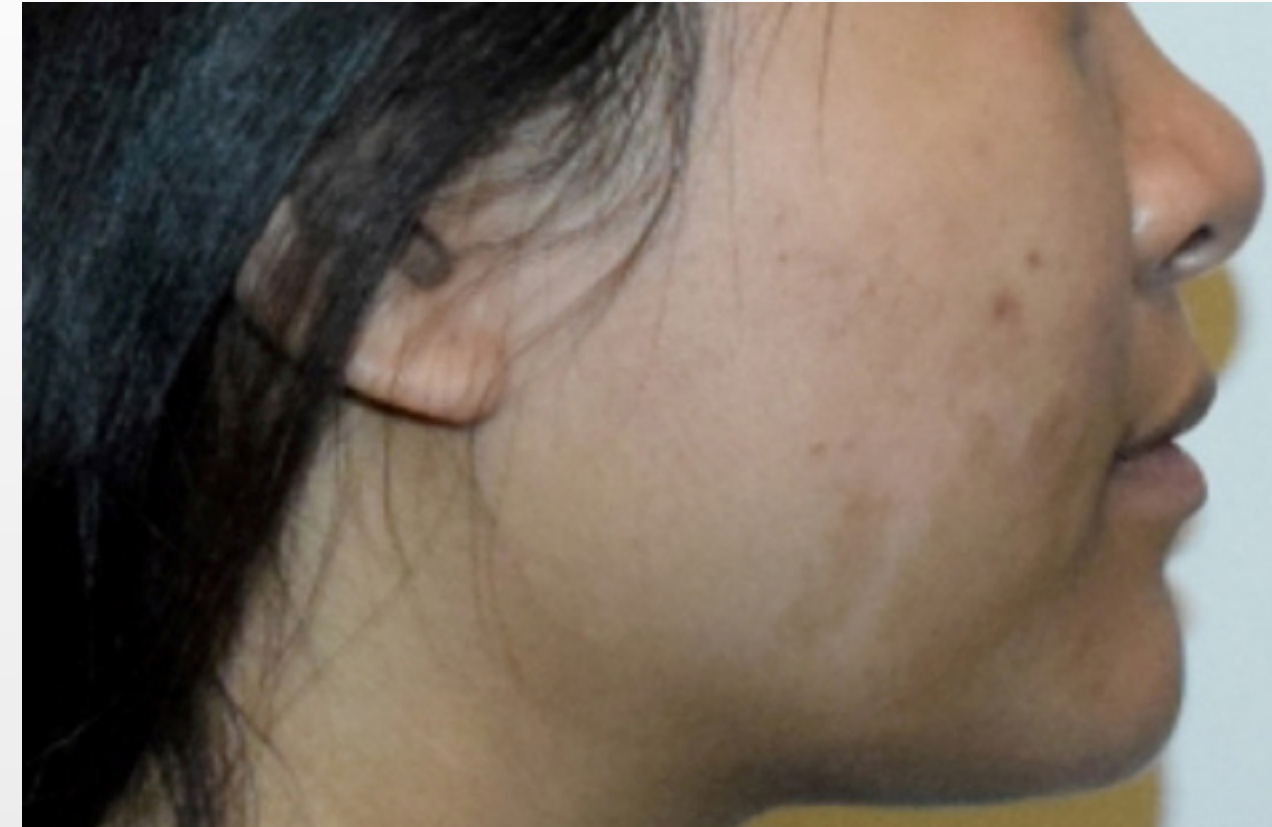Case courtesy of:

Dr. Lisa Davison
Powell, OH – USA

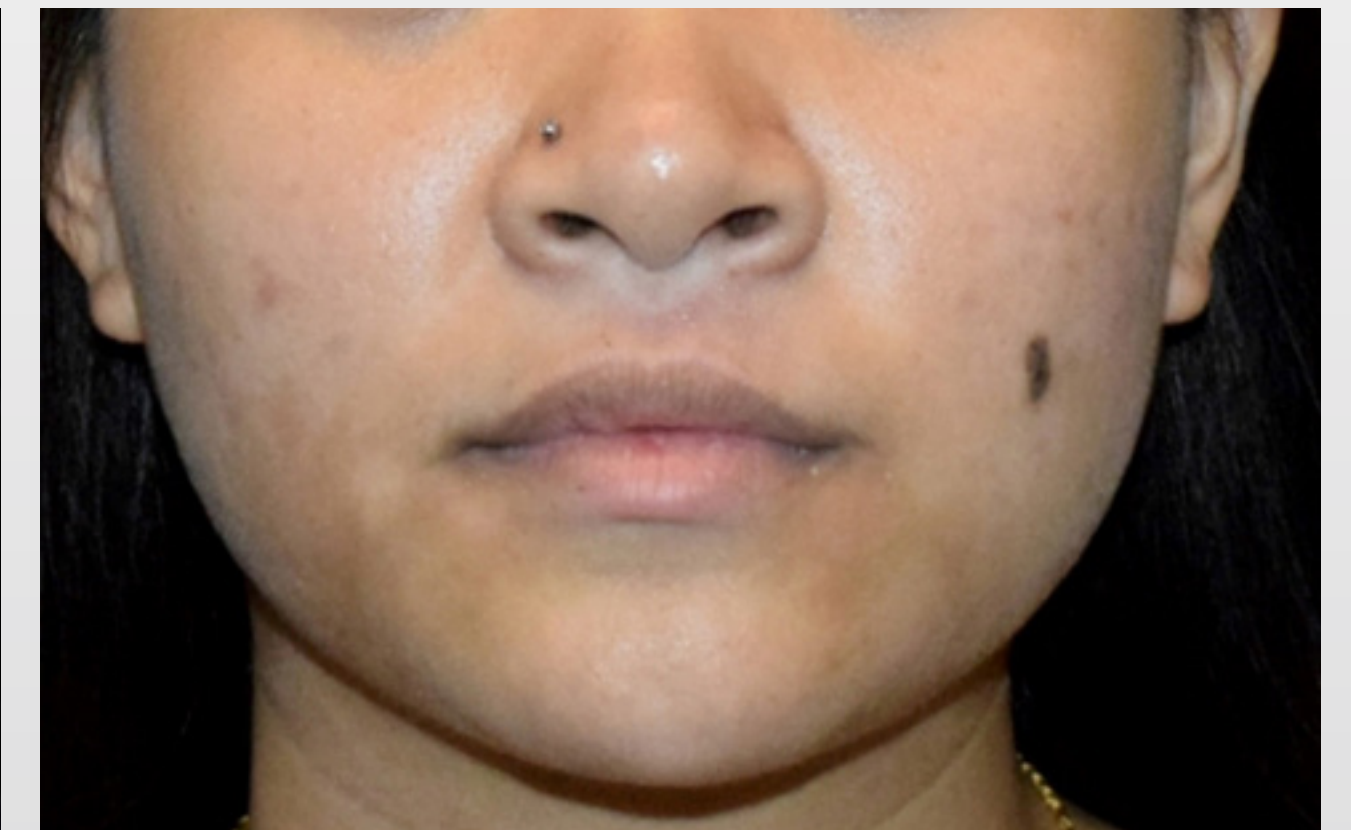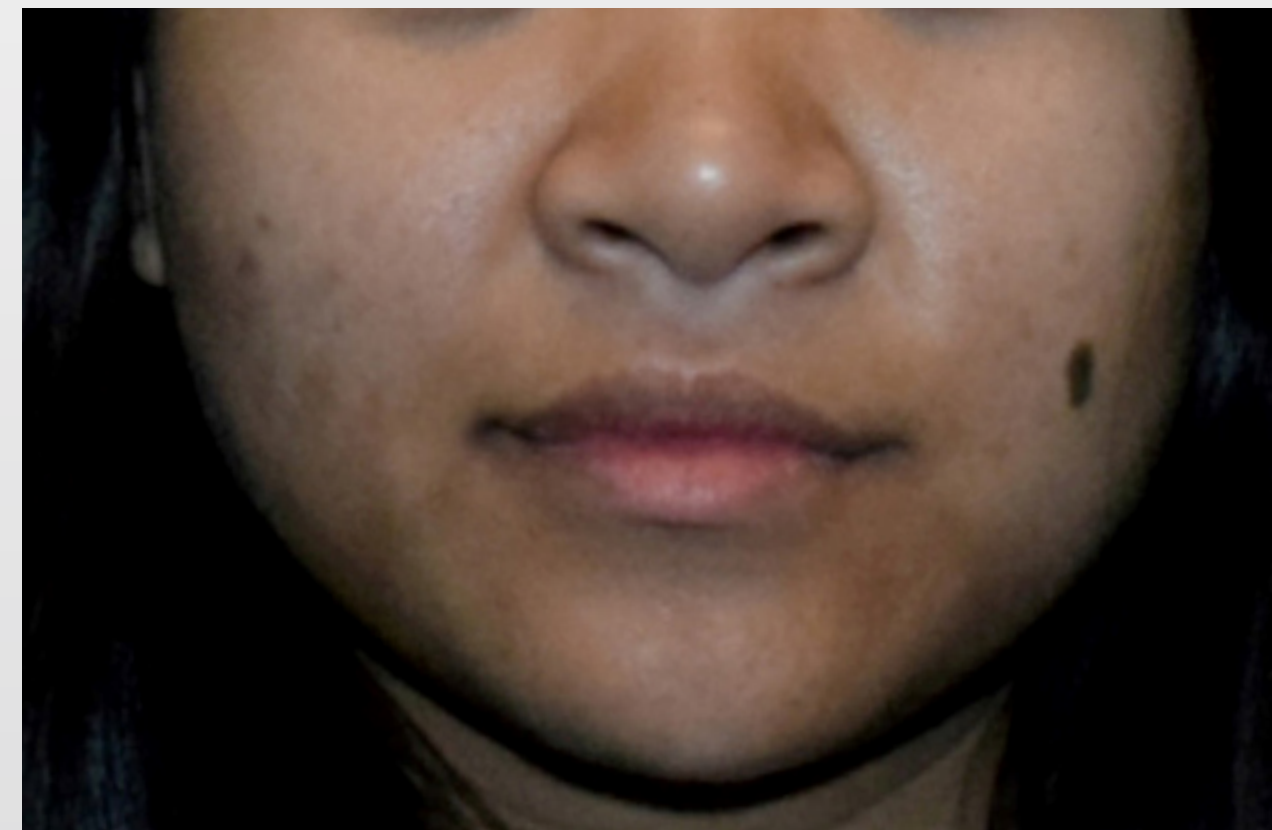Initial

Final

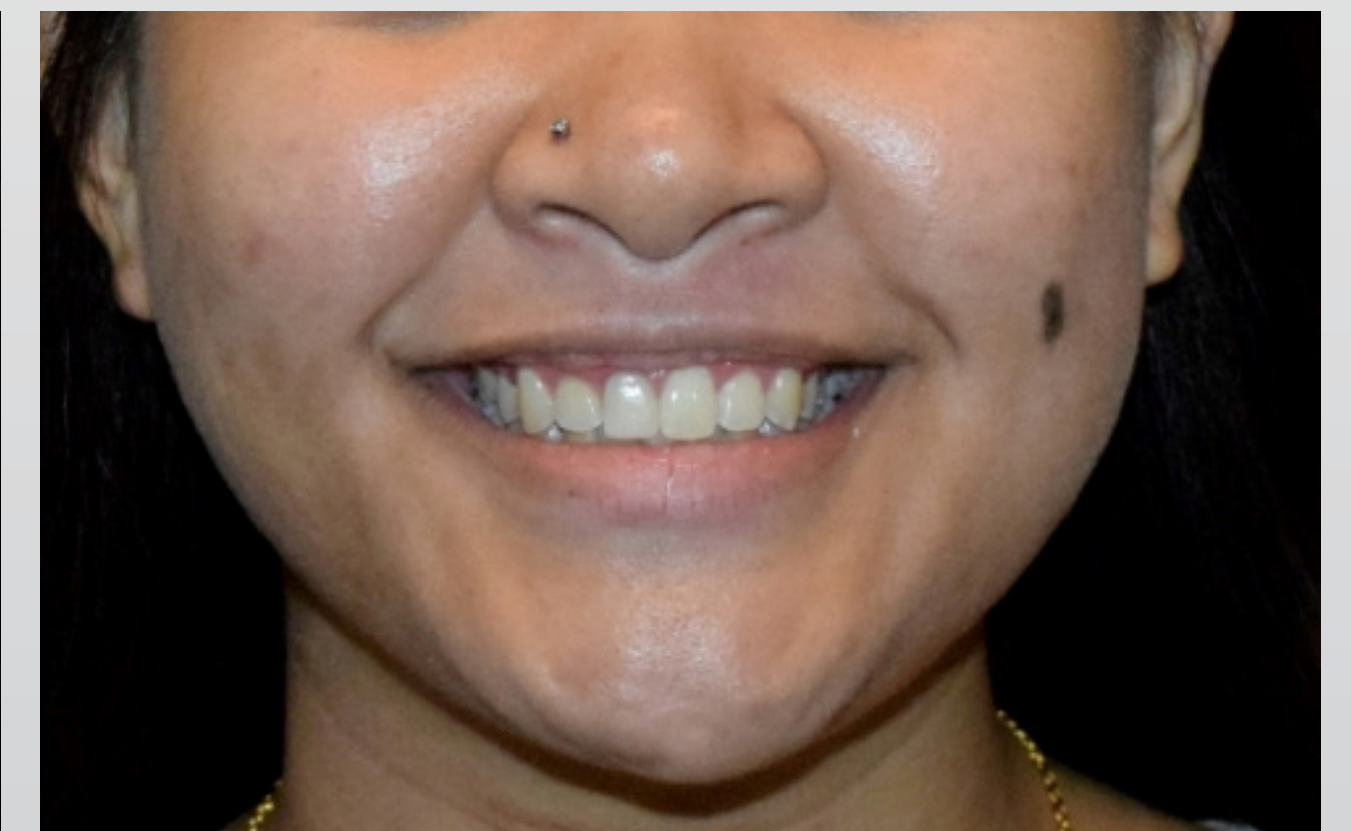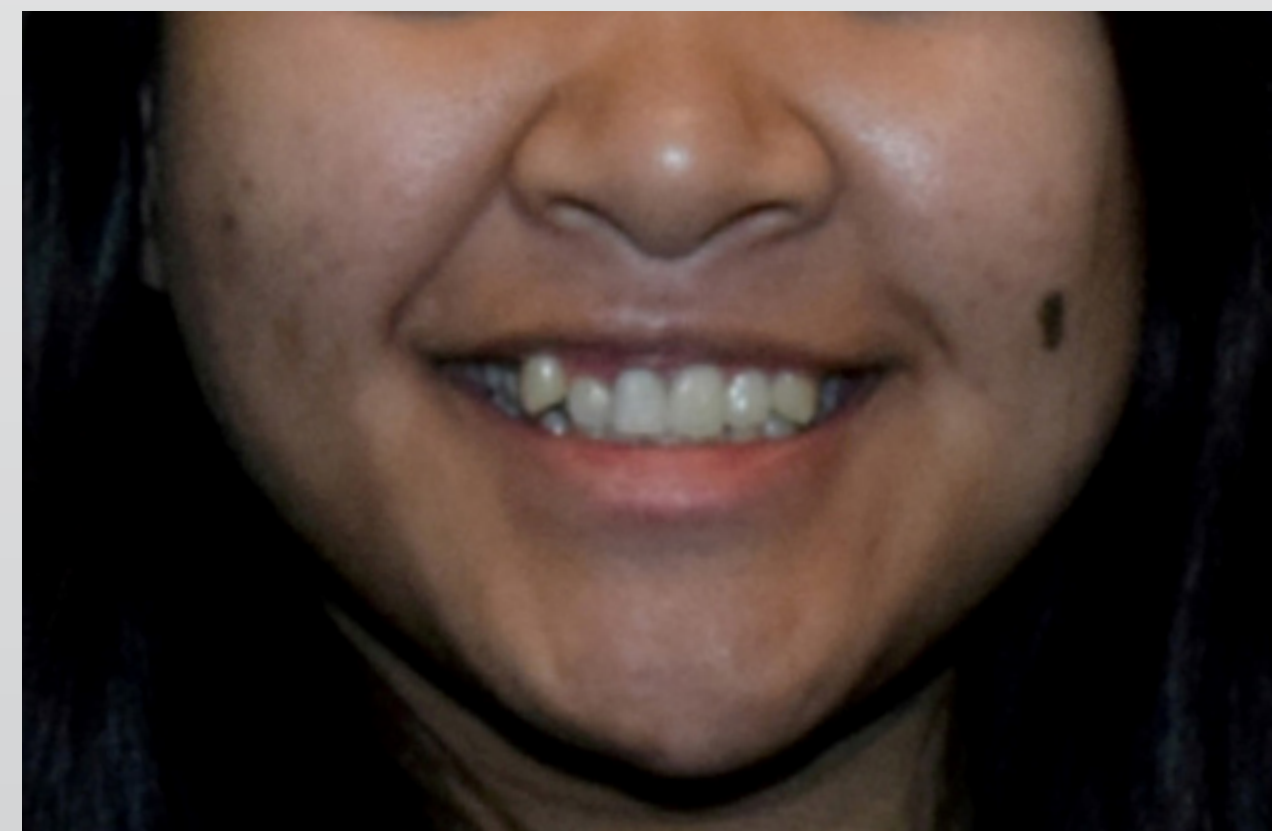Profile at rest



Face at rest



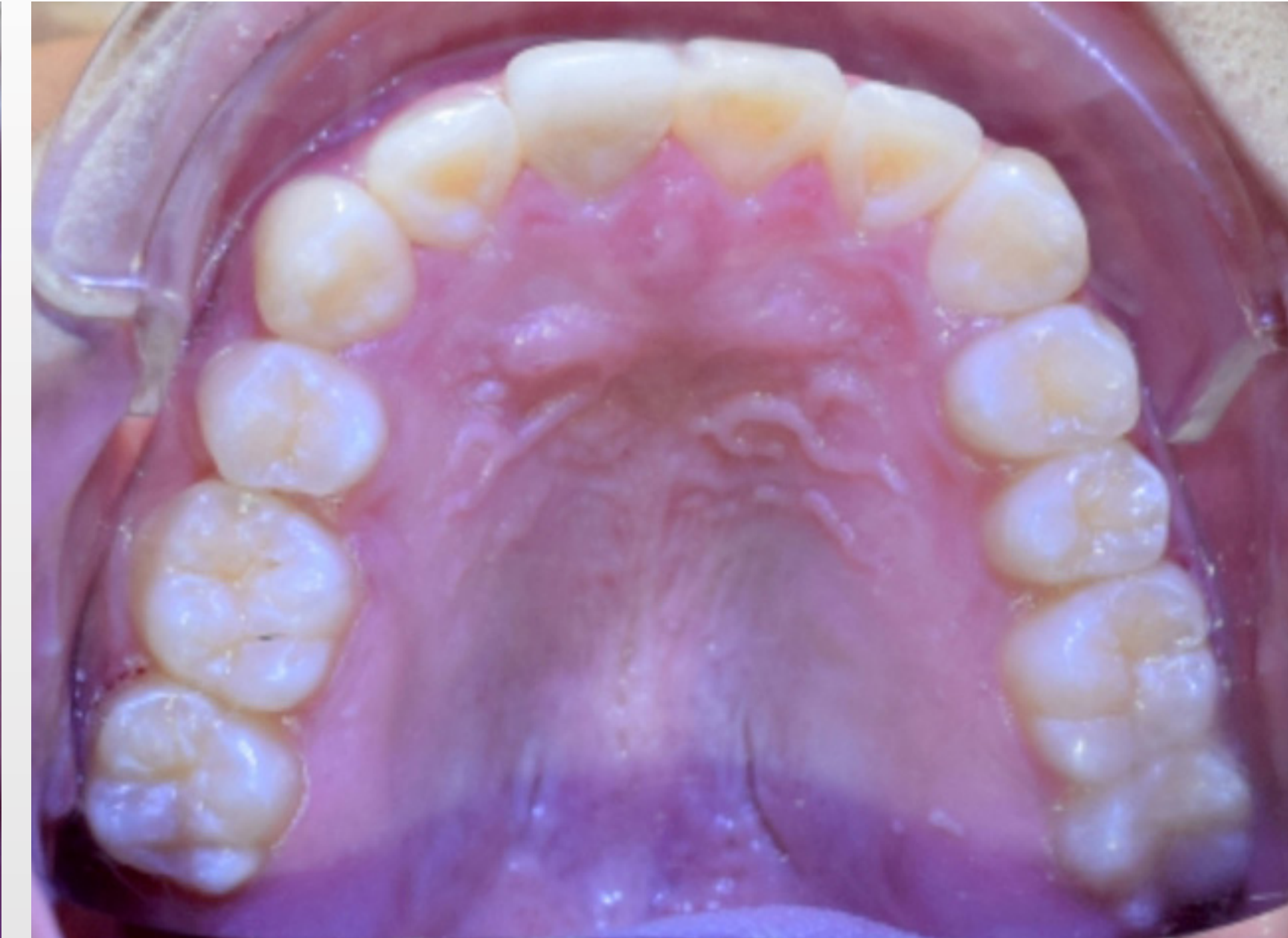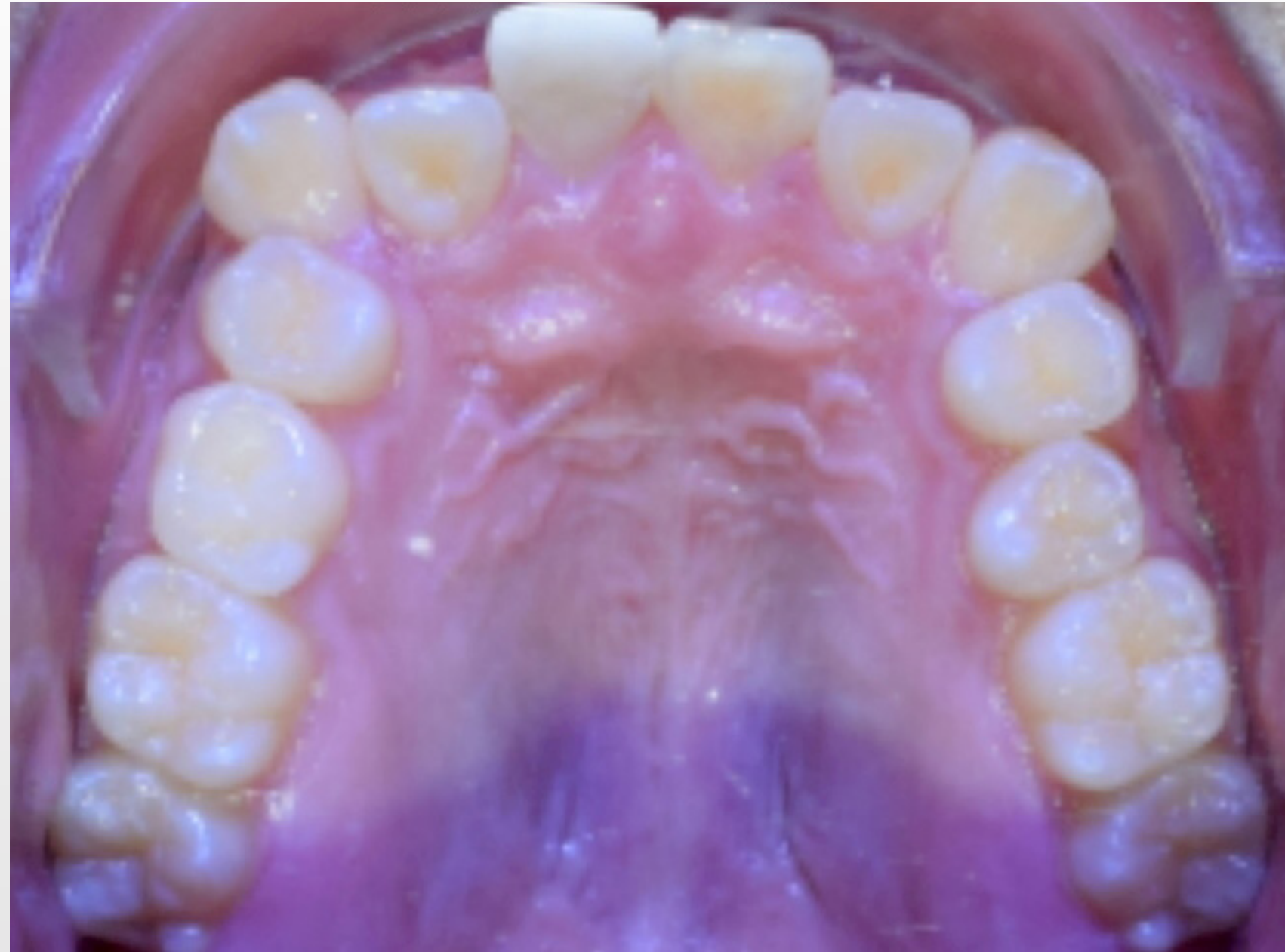Face smiling



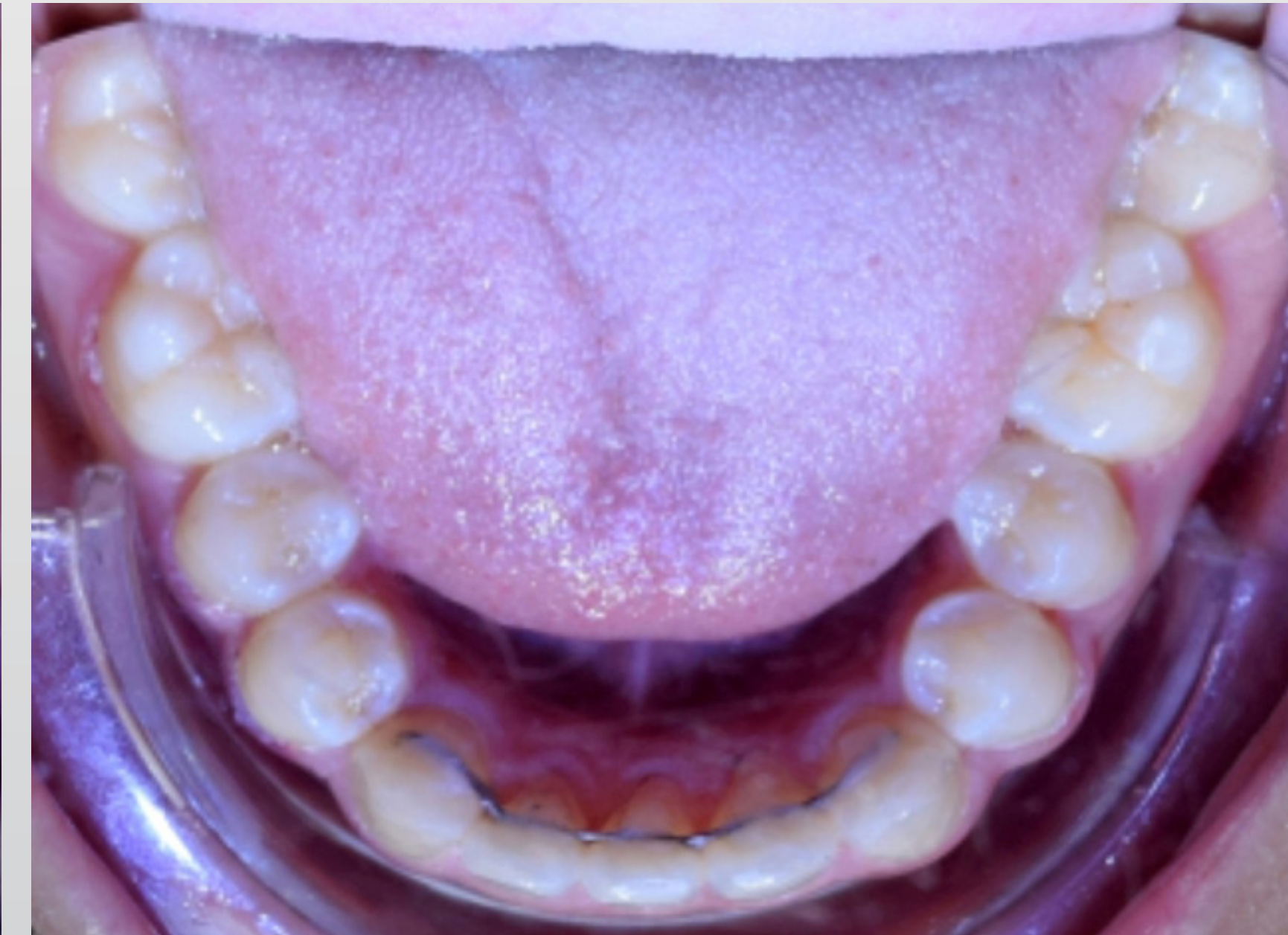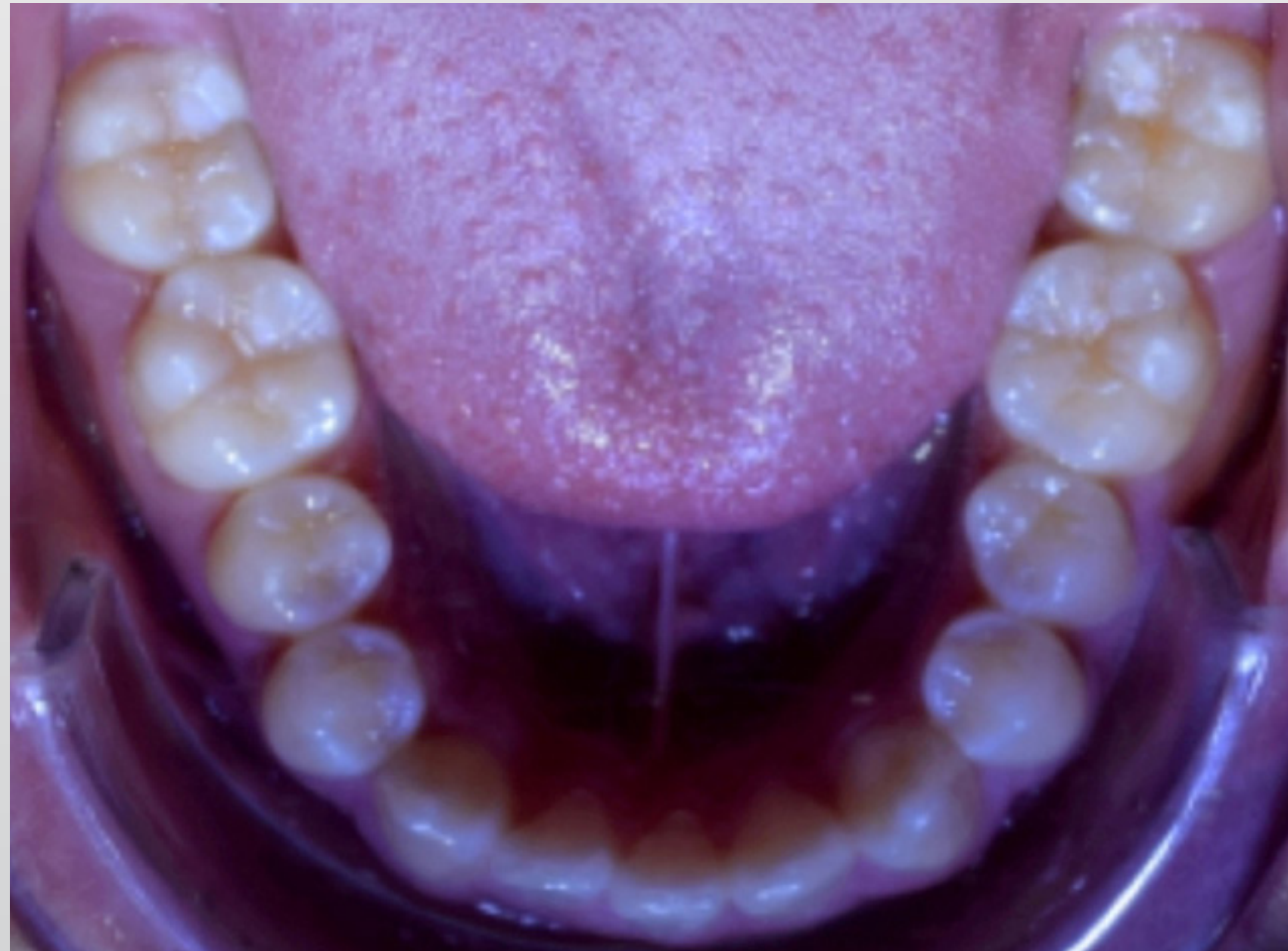Initial

Final

**Occlusal –
maxillary**



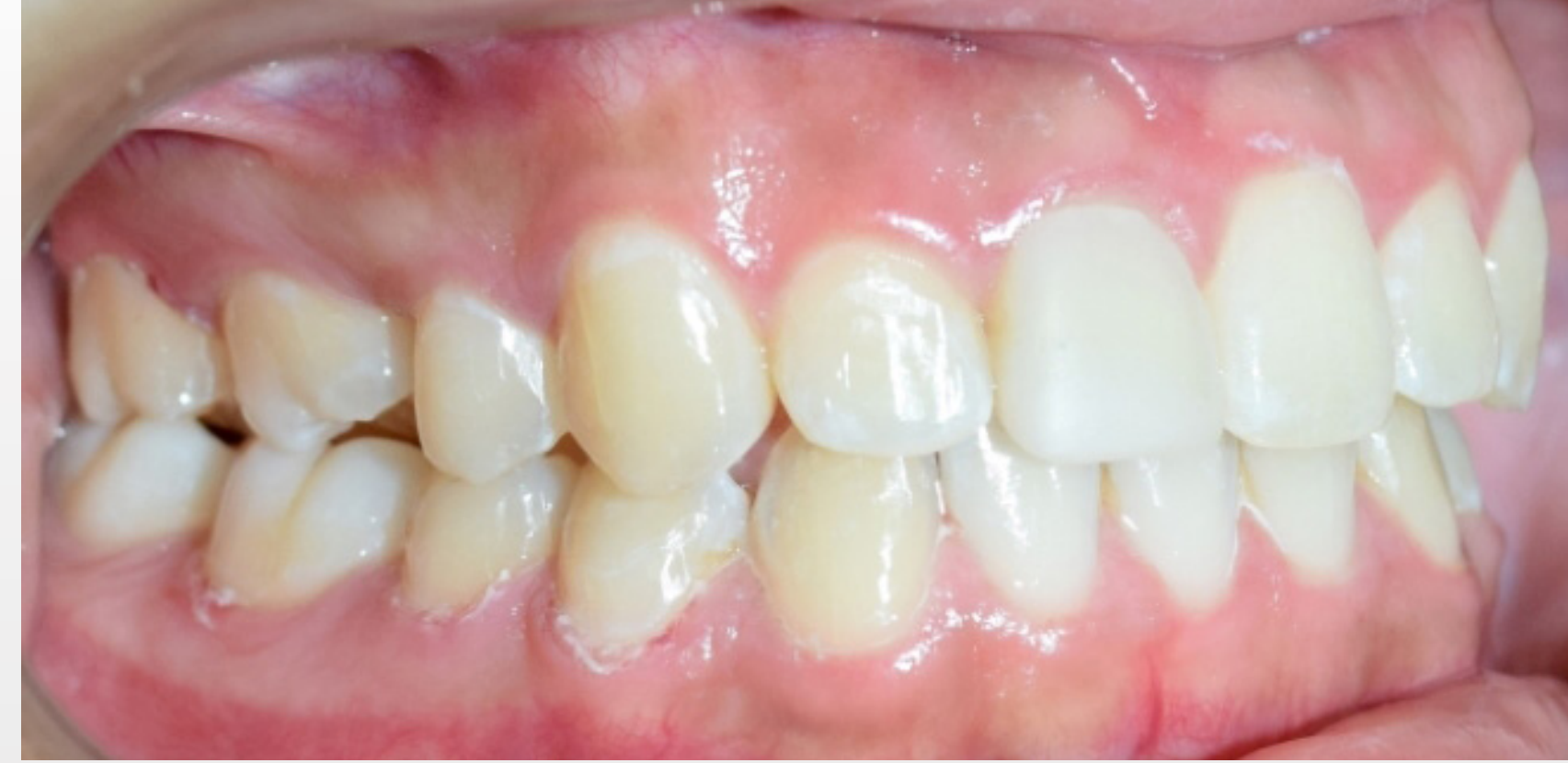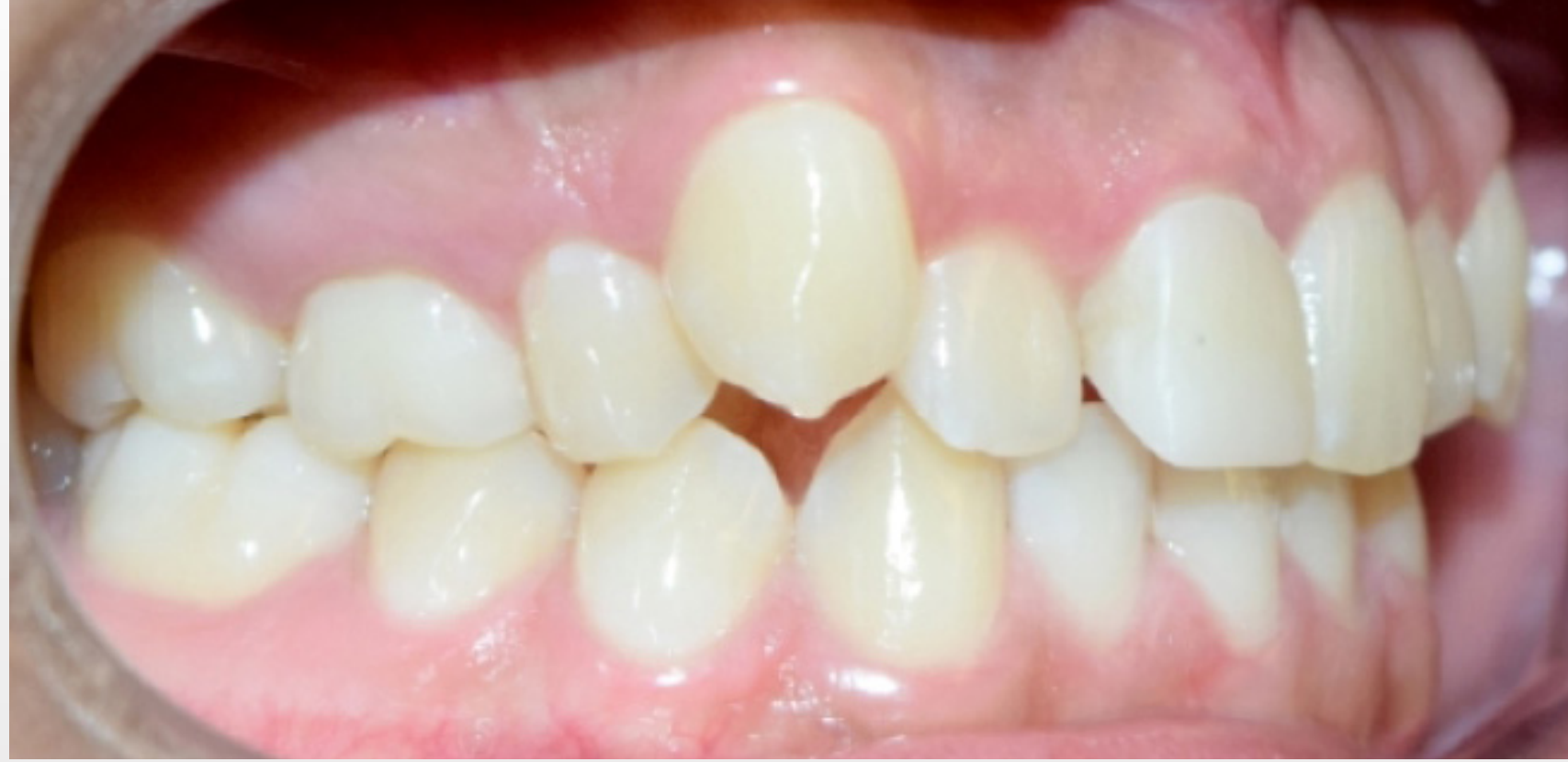**Occlusal –
mandibular**



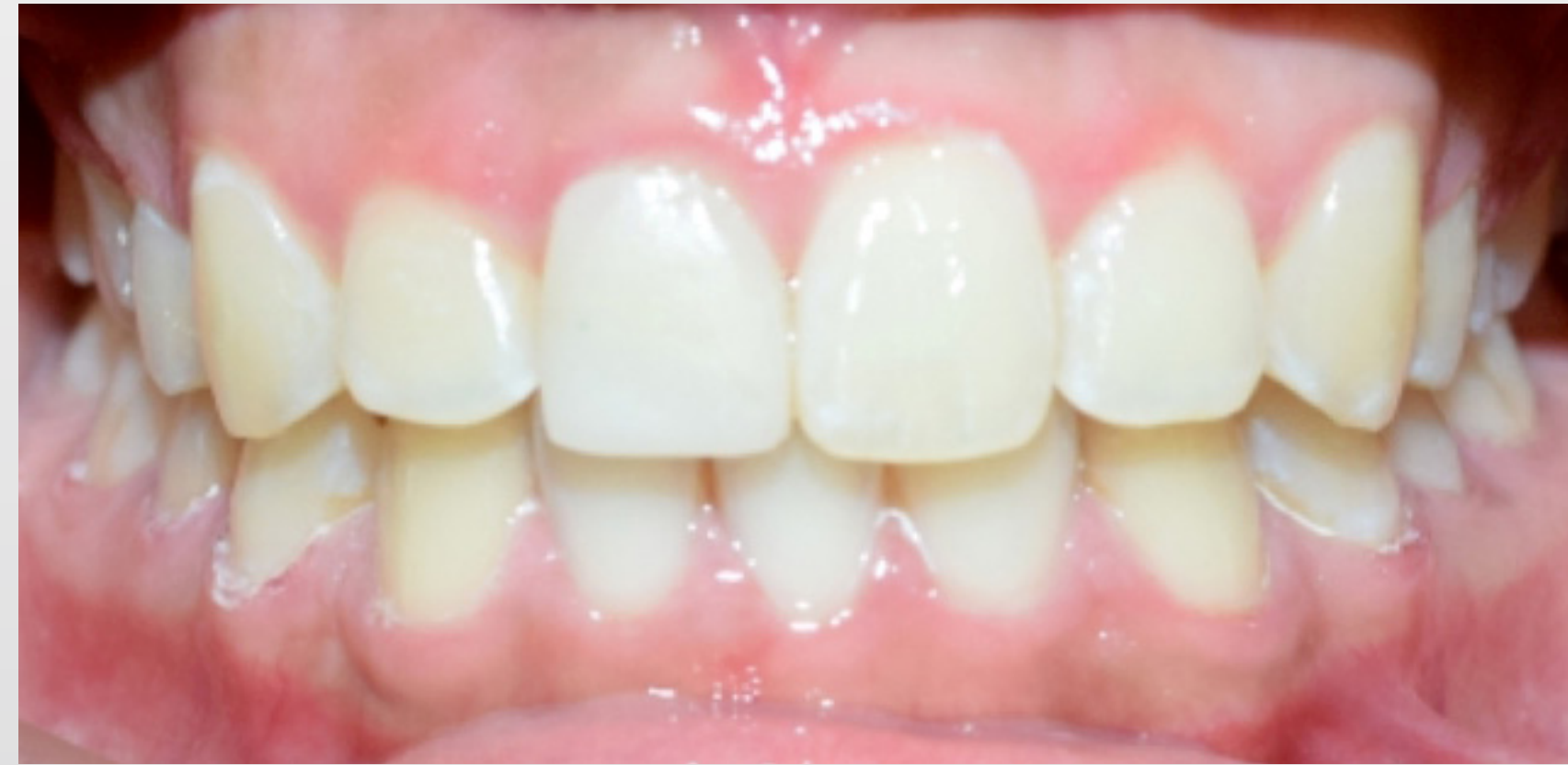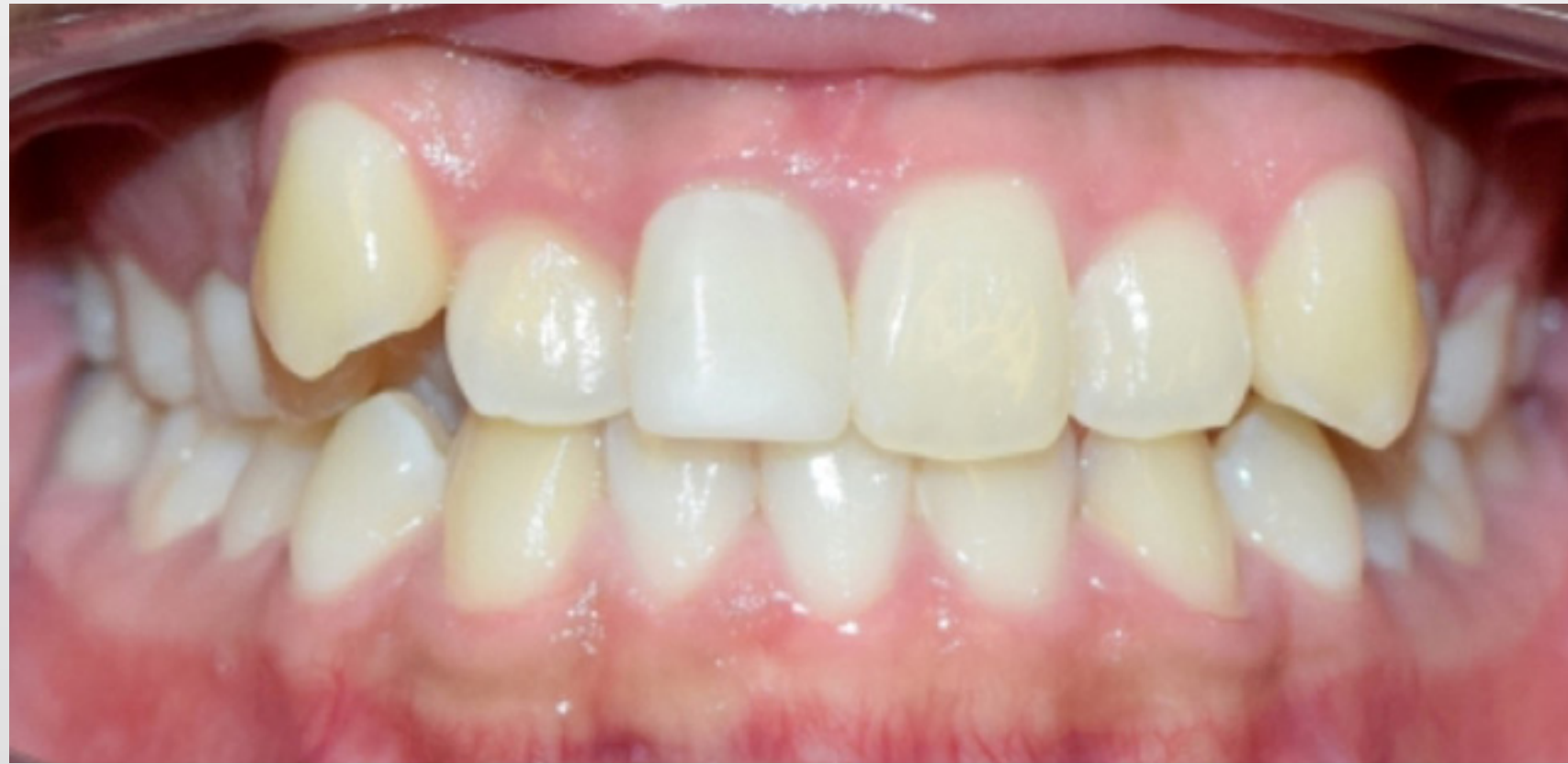Initial

Final

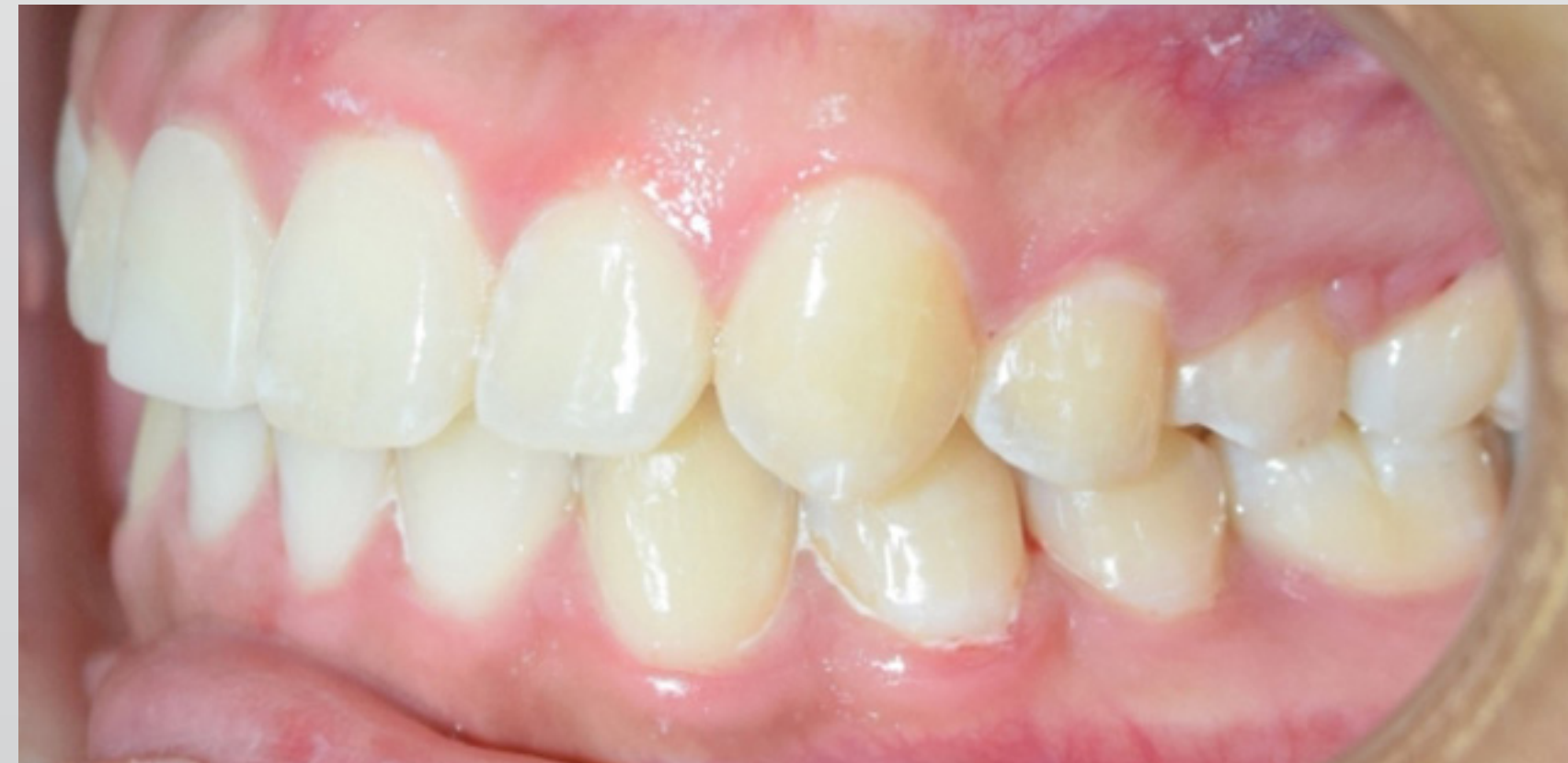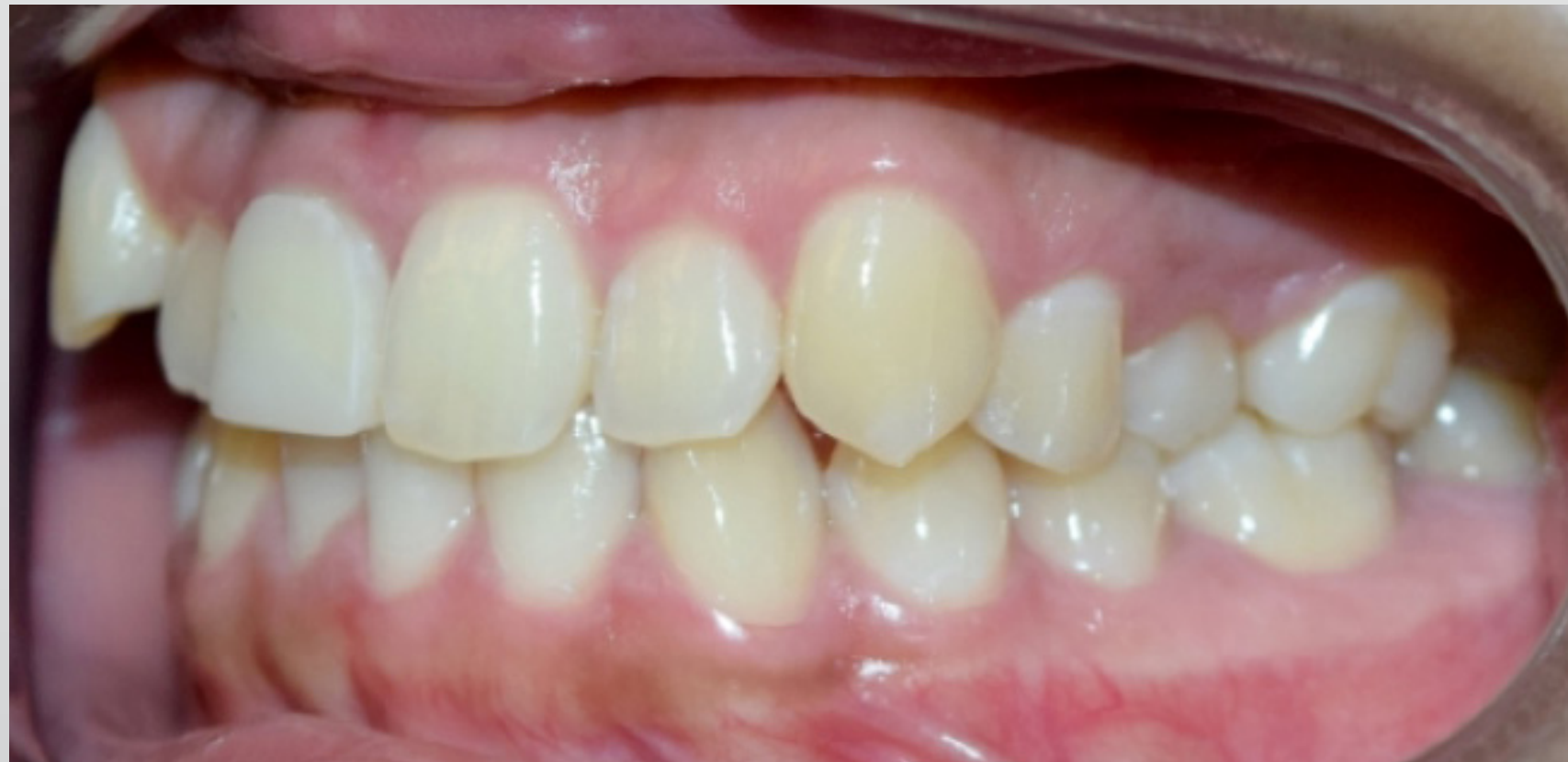**Retracted
buccal – right**



**Retracted
anterior biting**

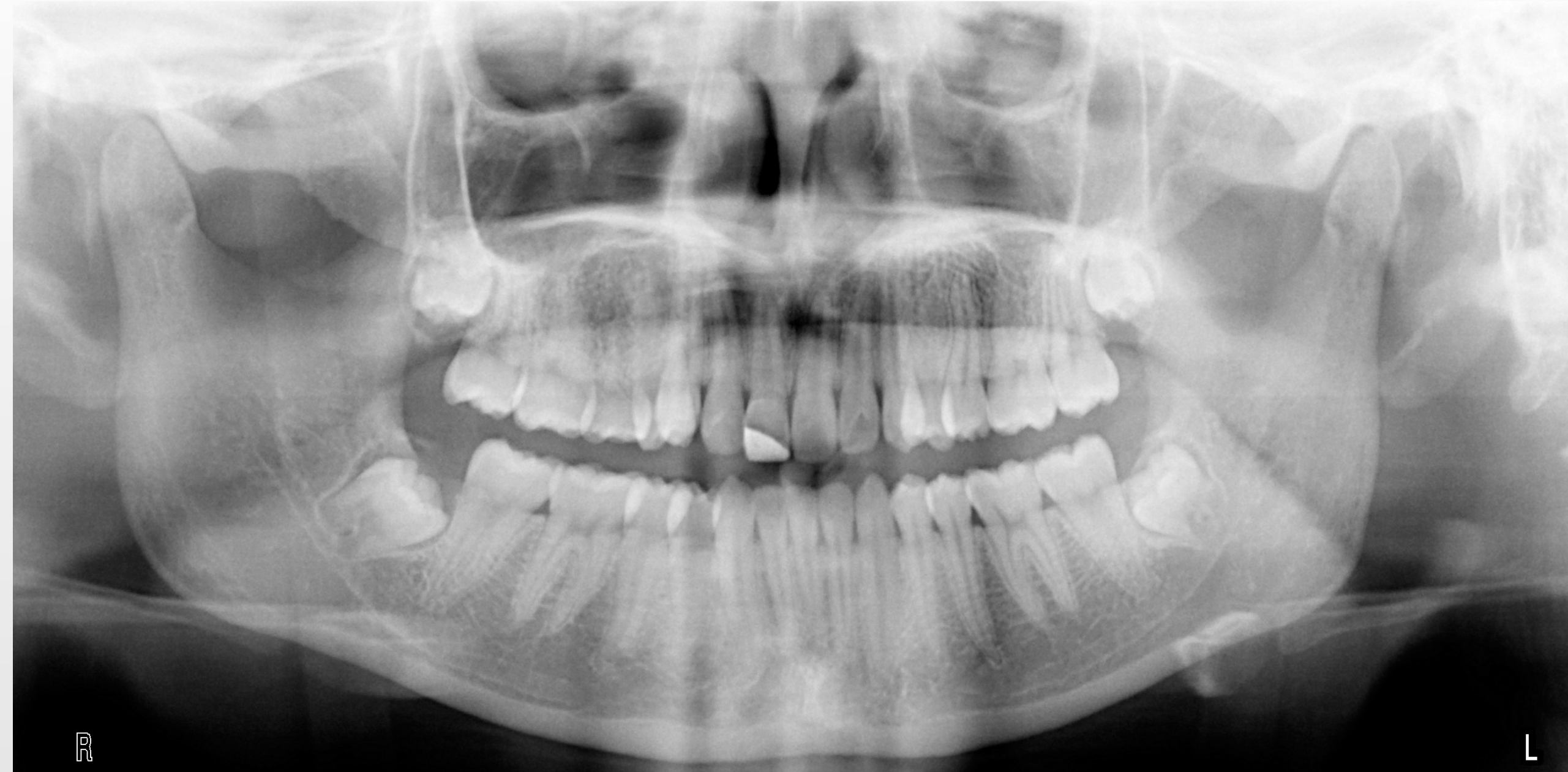

**Retracted
buccal – left**

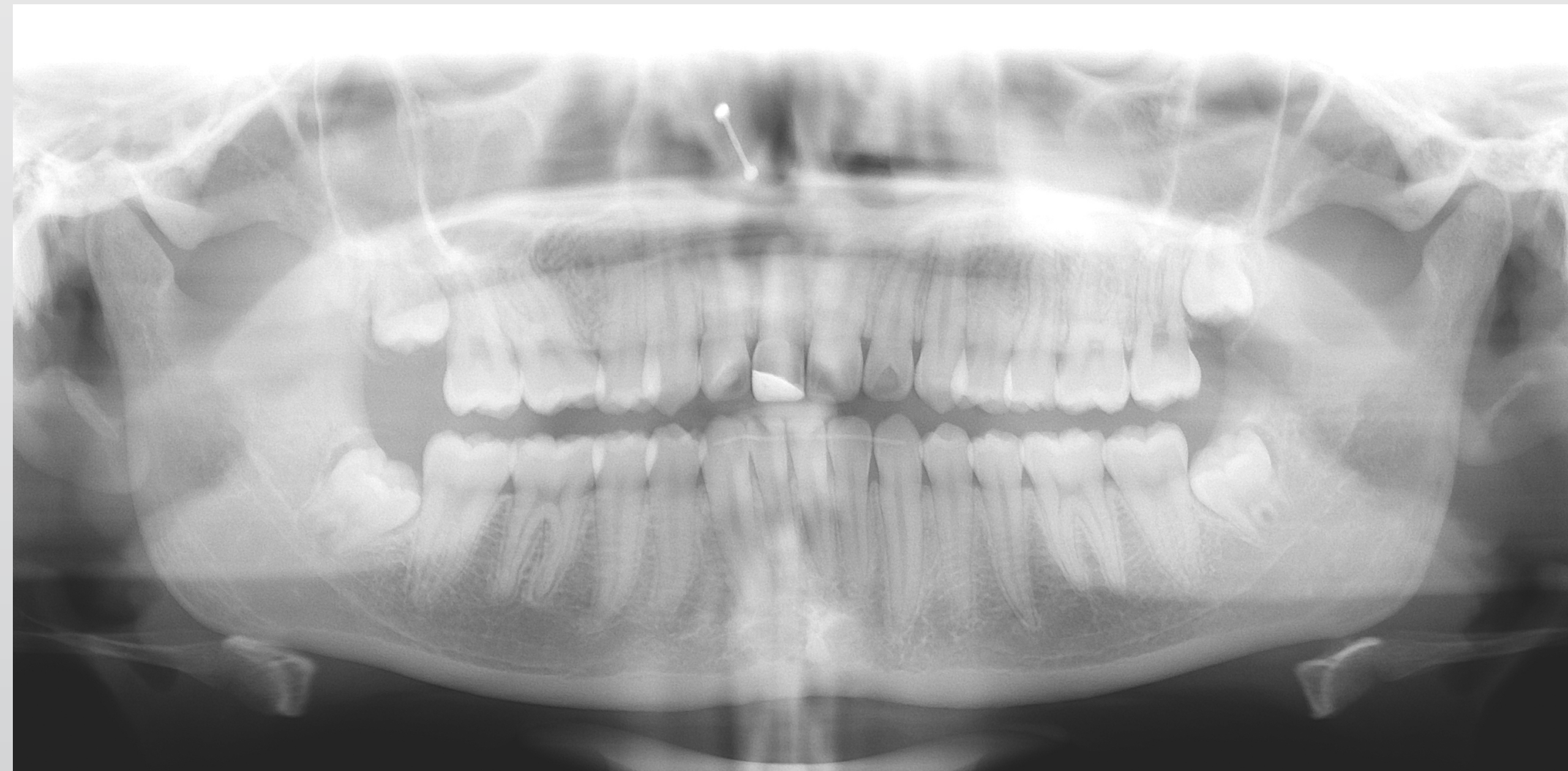

Panoramic radiograph

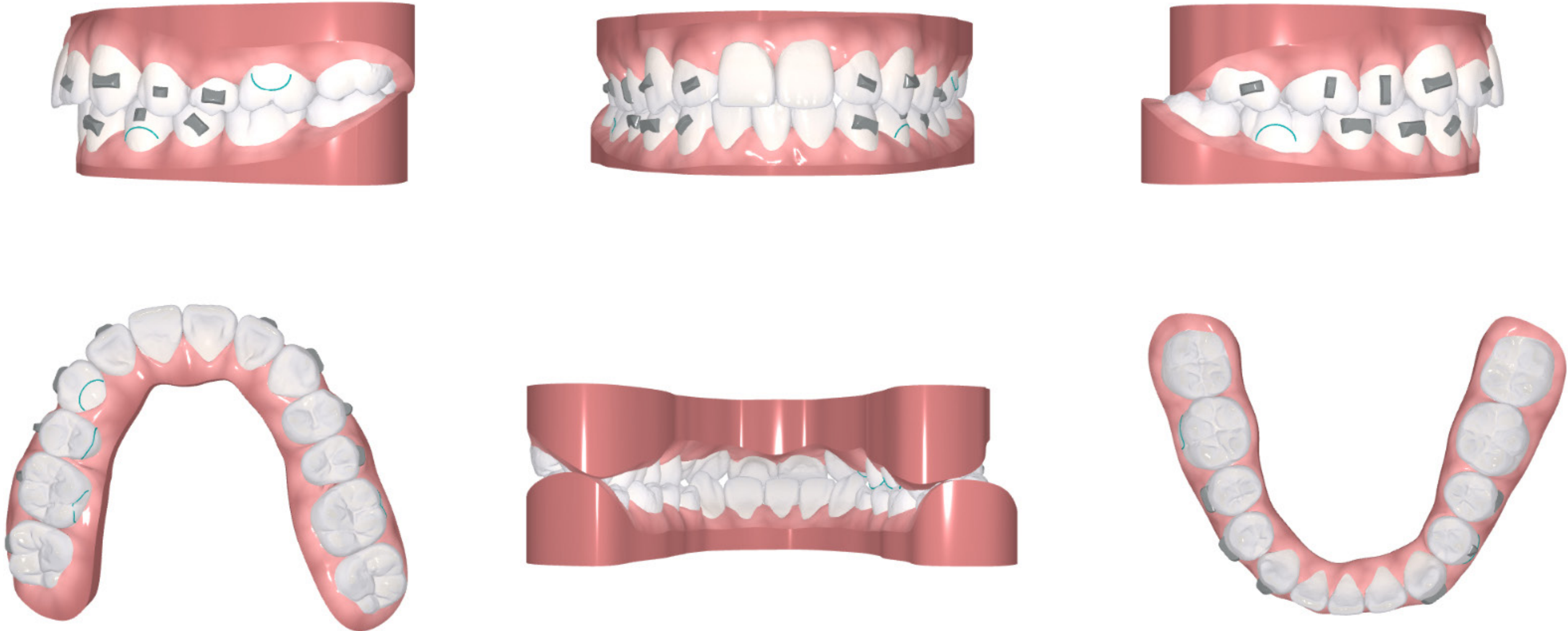
Initial



Final



Initial Tx Design



Simulated gingiva, root and tooth movements. Actual clinical results may vary.

Movements ^

IPR Detail ^



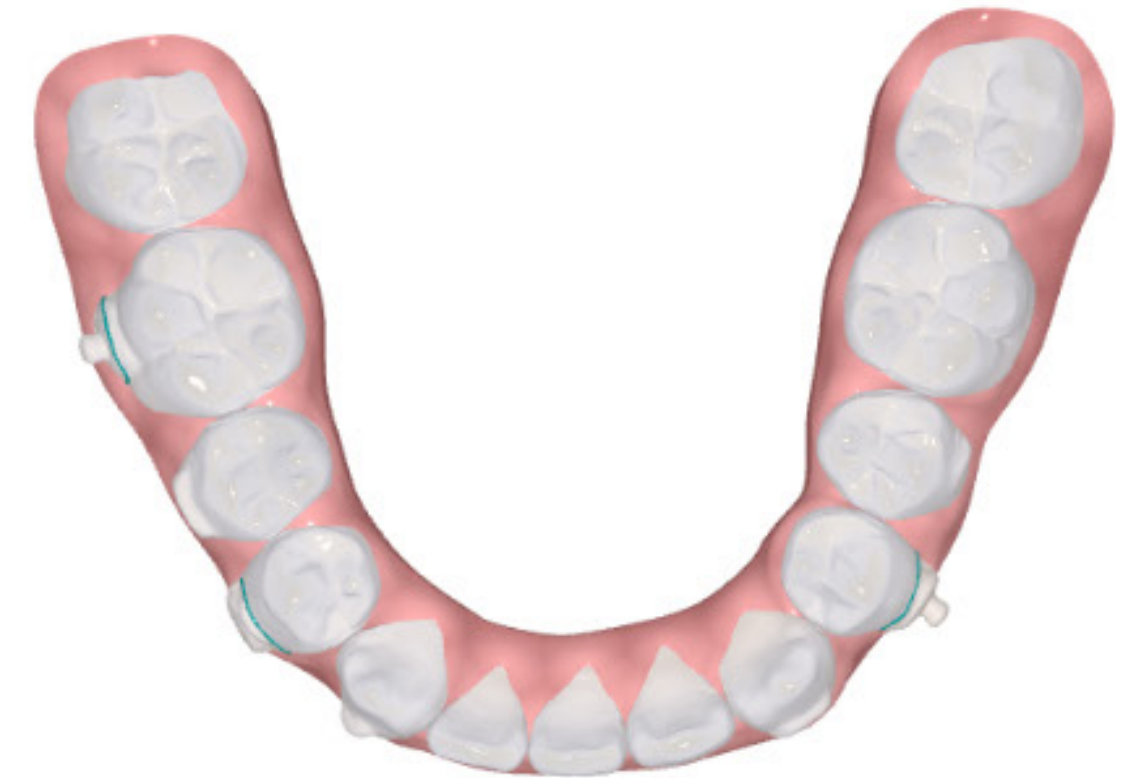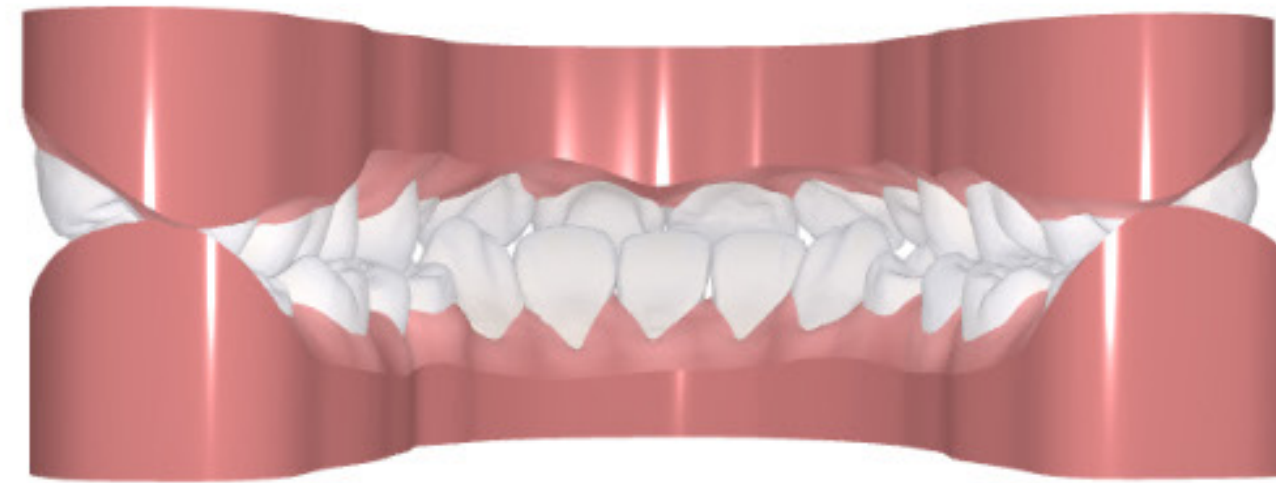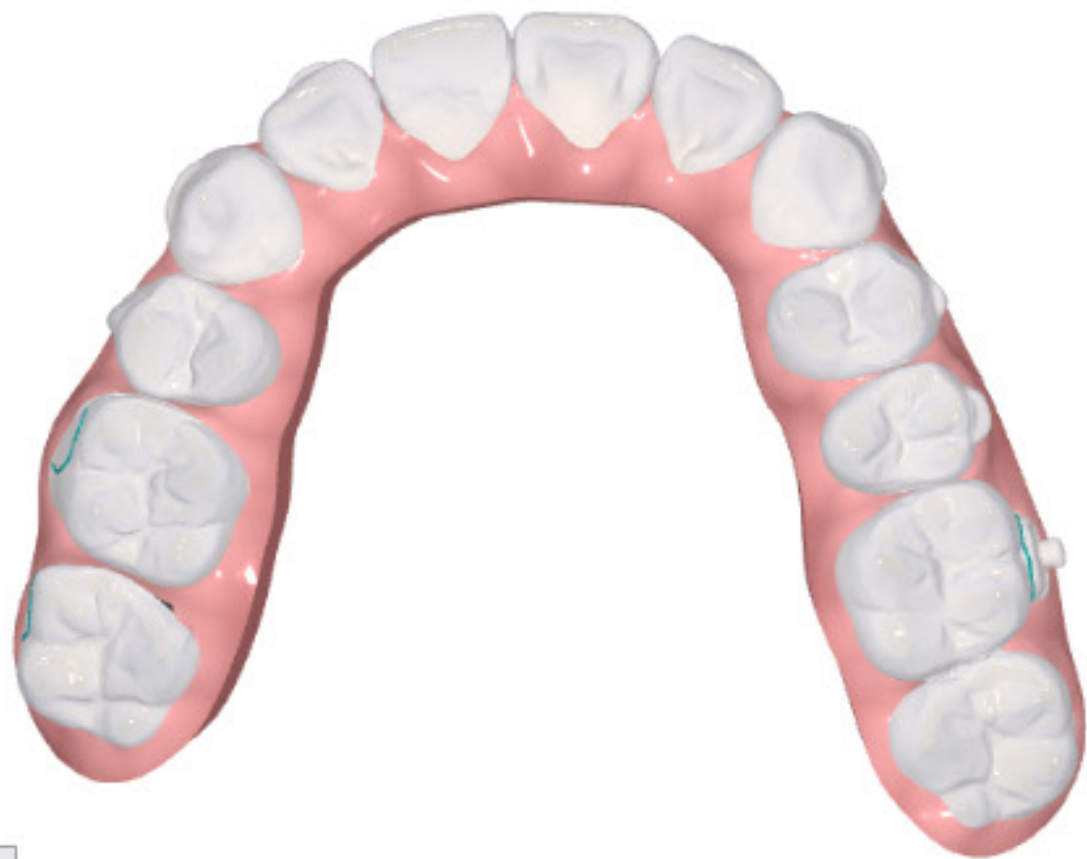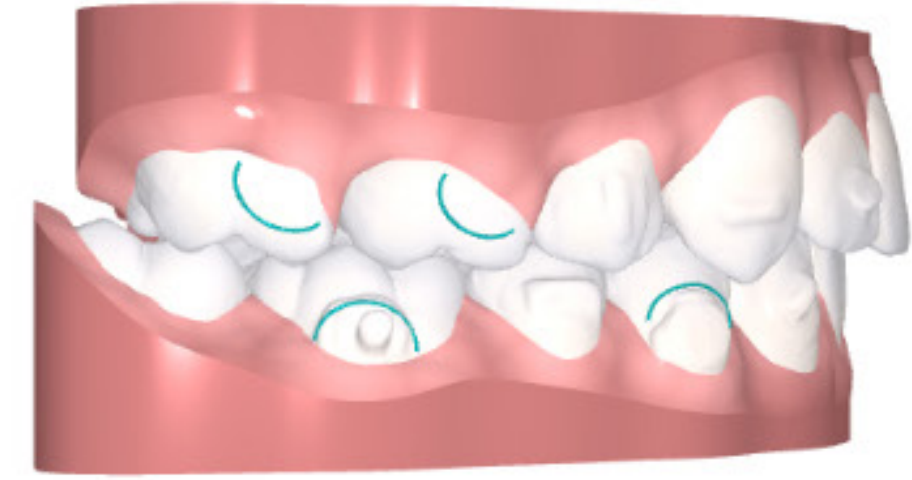
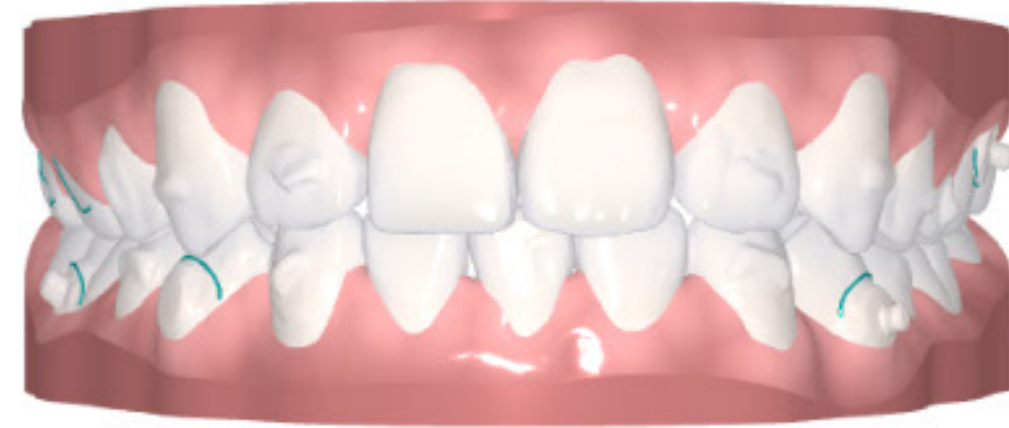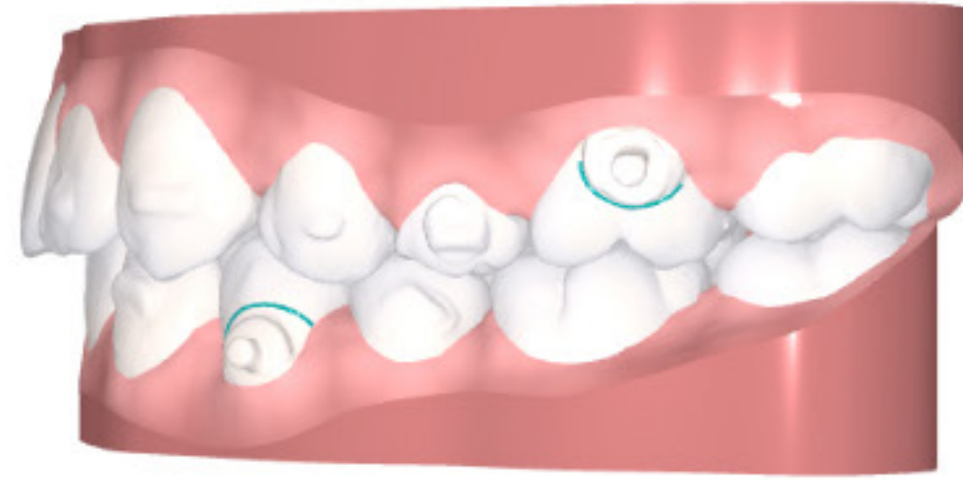
Aligners



Compare Stages



Final Tx Design



Simulated gingiva, root and tooth movements. Actual clinical results may vary.

Movements ^



Compare Stages

